

# ***L'ECOGRAFIA INTERVENTISTICA NELLA DIVERTICOLITE IN FASE ACUTA***



***S. Sartori, P. Tombesi, F. Di Vece***

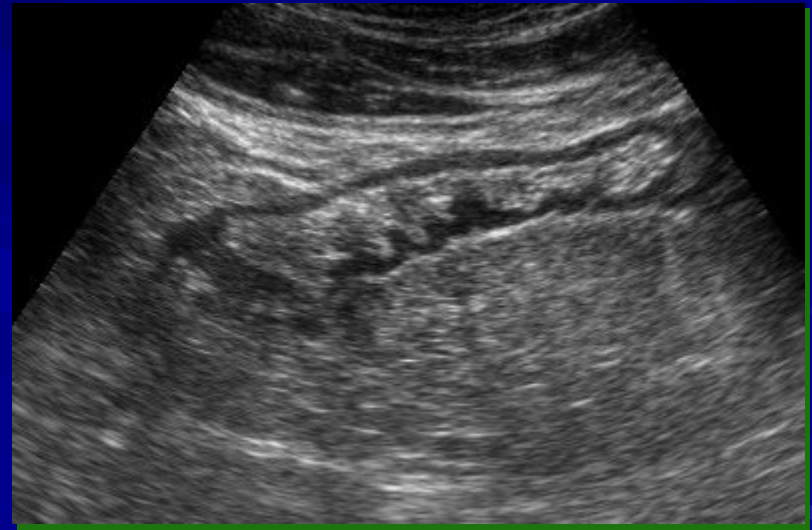***Modulo Dipartimentale di Ecografia Interventistica***

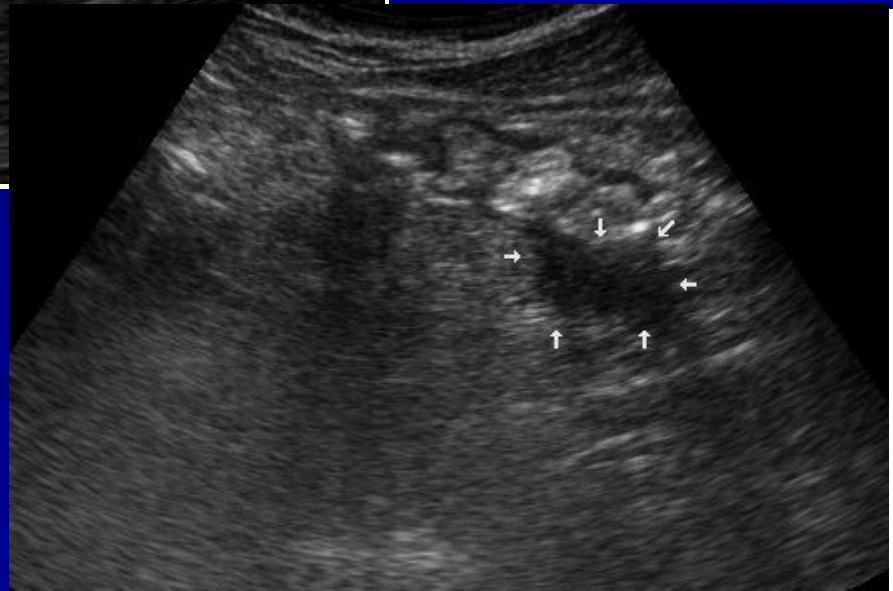
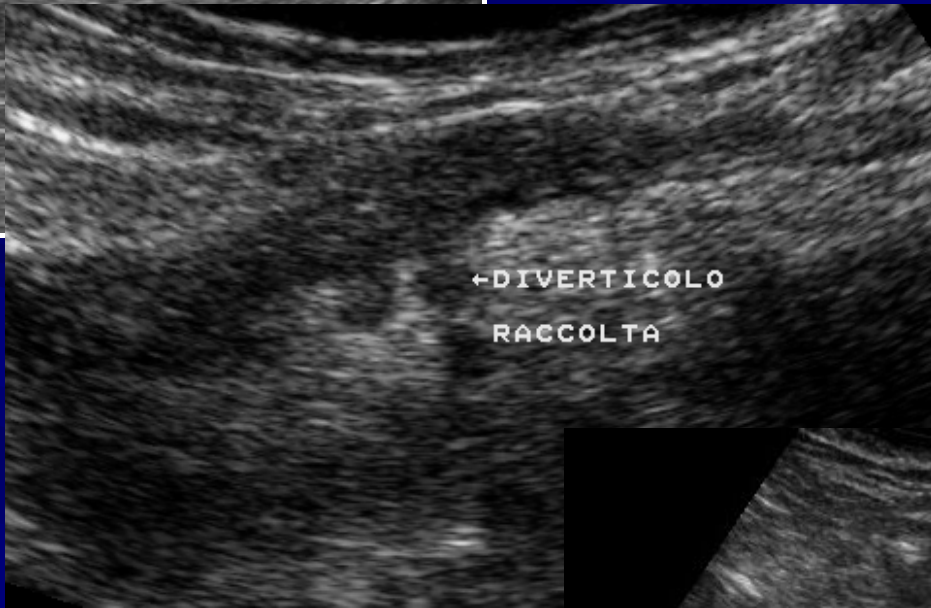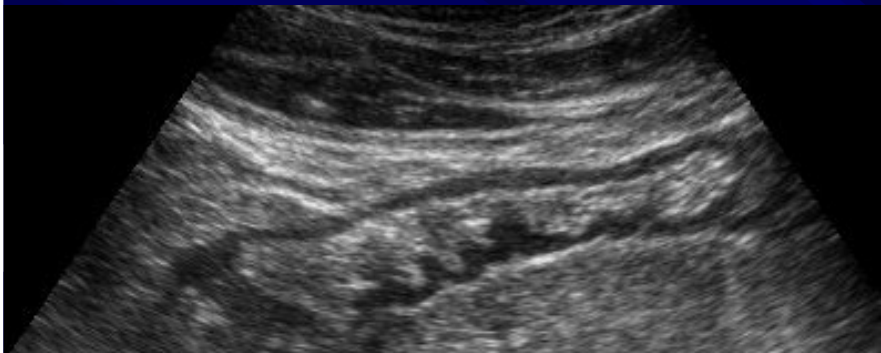
***Az. Ospedaliera Universitaria S. Anna Ferrara***

# ***CHE RUOLO PER L'ECOGRAFIA?***

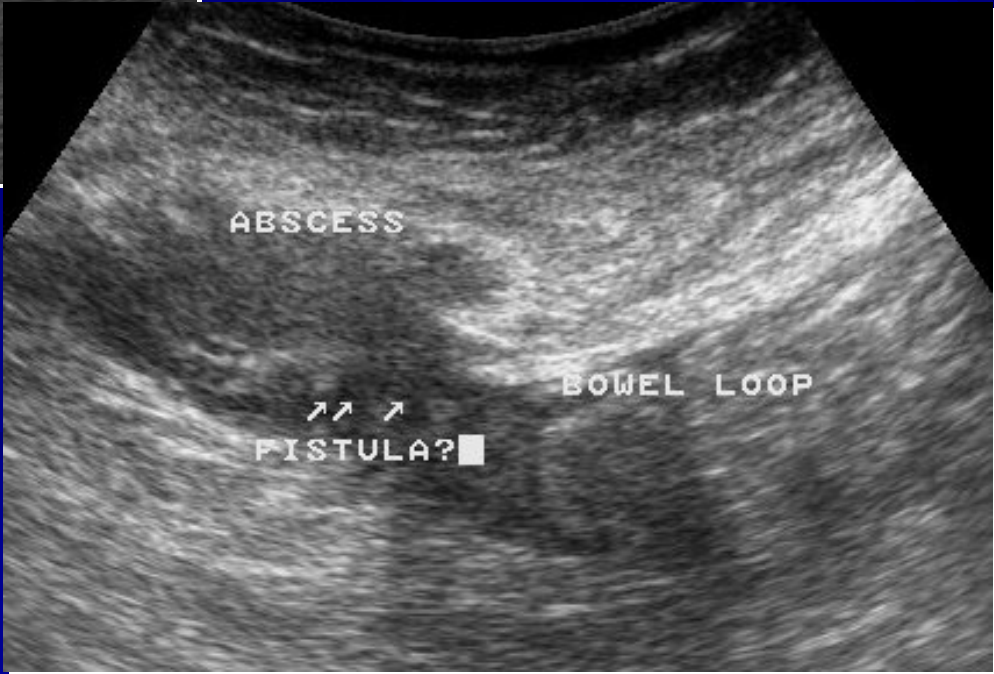
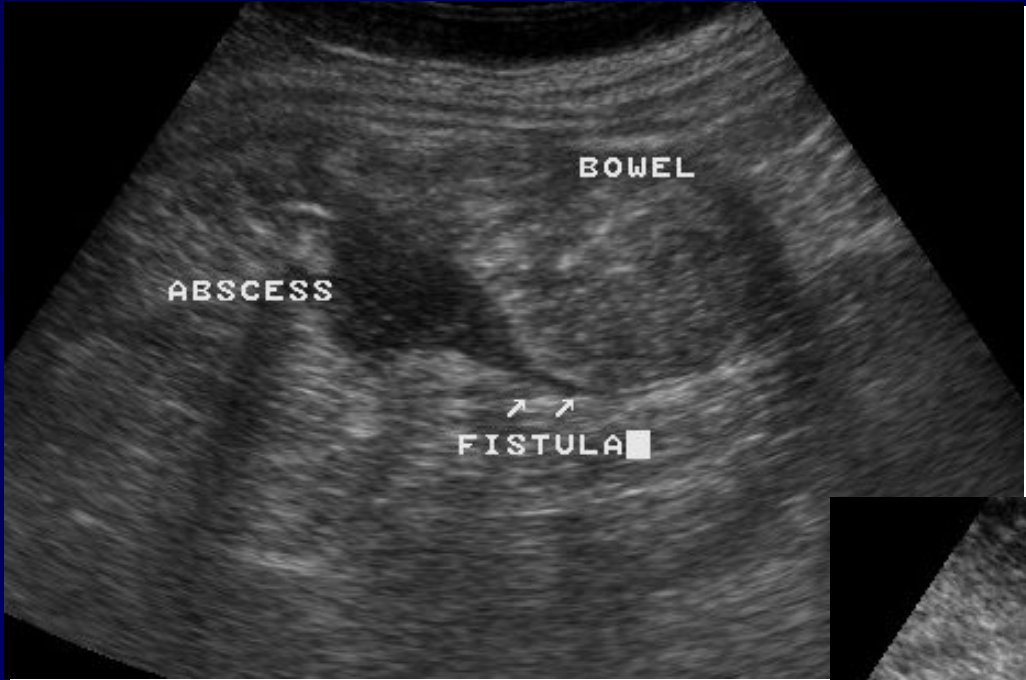

*Proprio vero?*

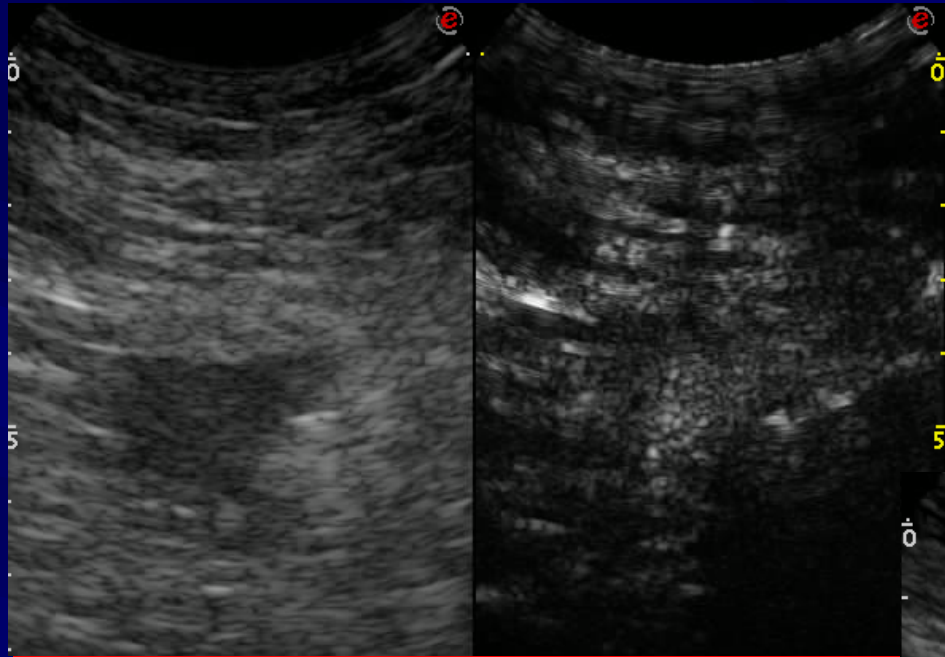




# DIAGNOSI

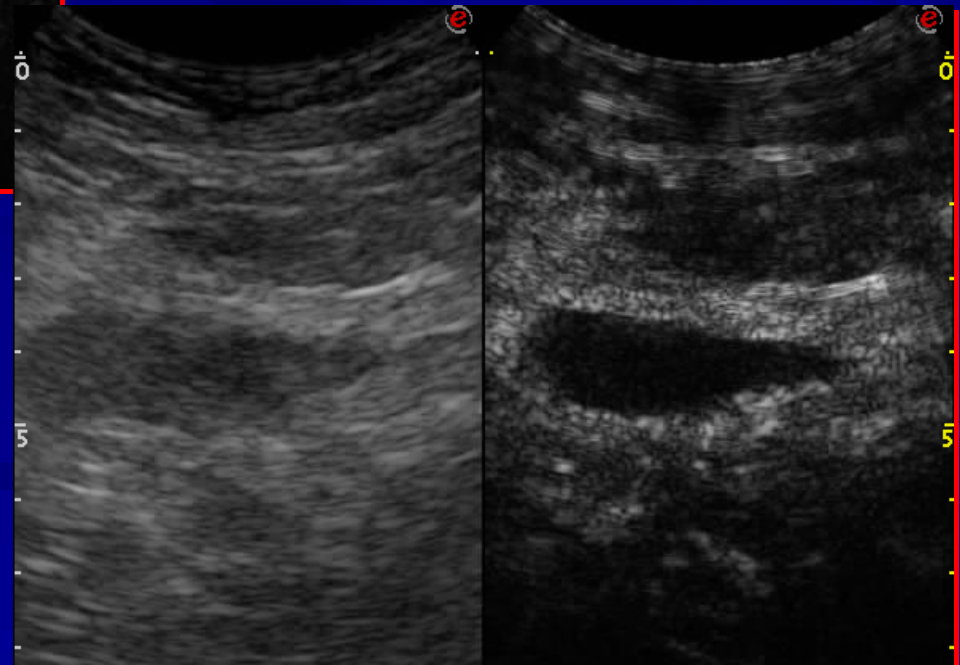


***M.d.C.!***

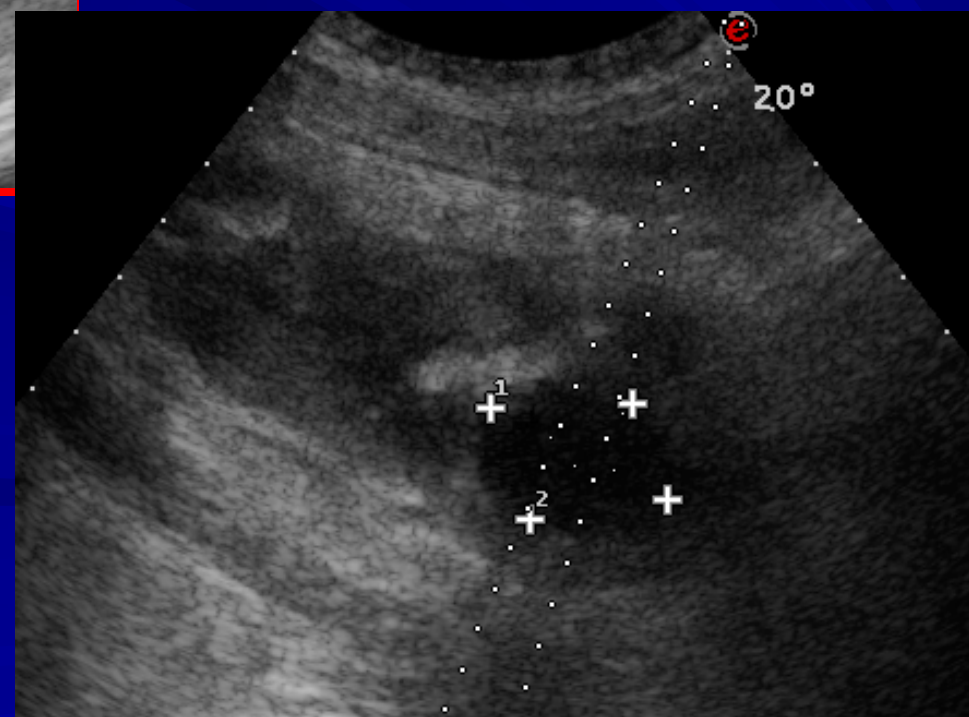

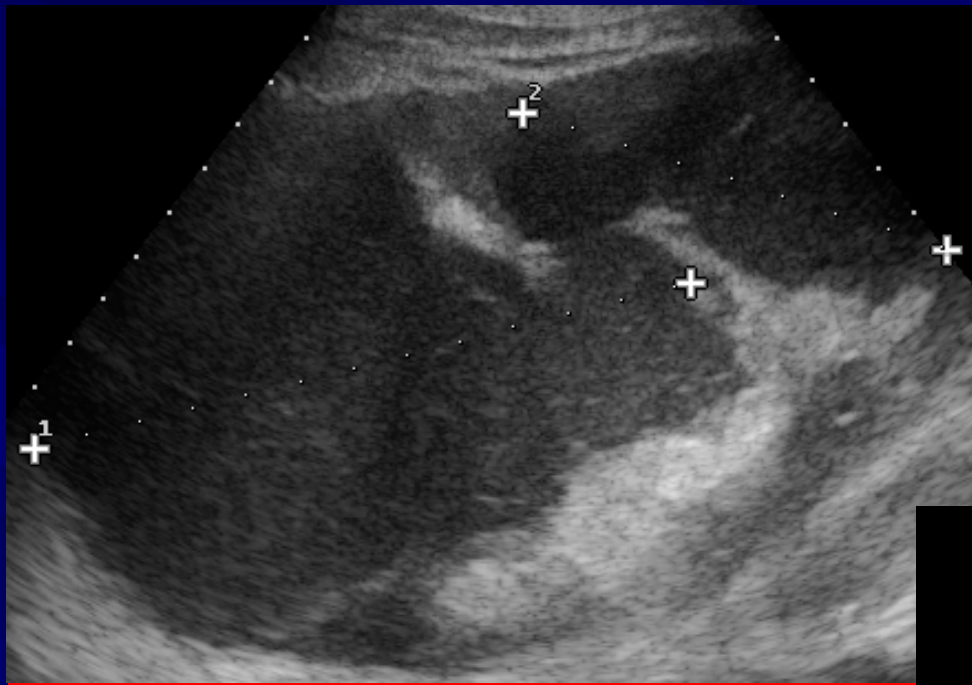


***Ansa ripiegata!***

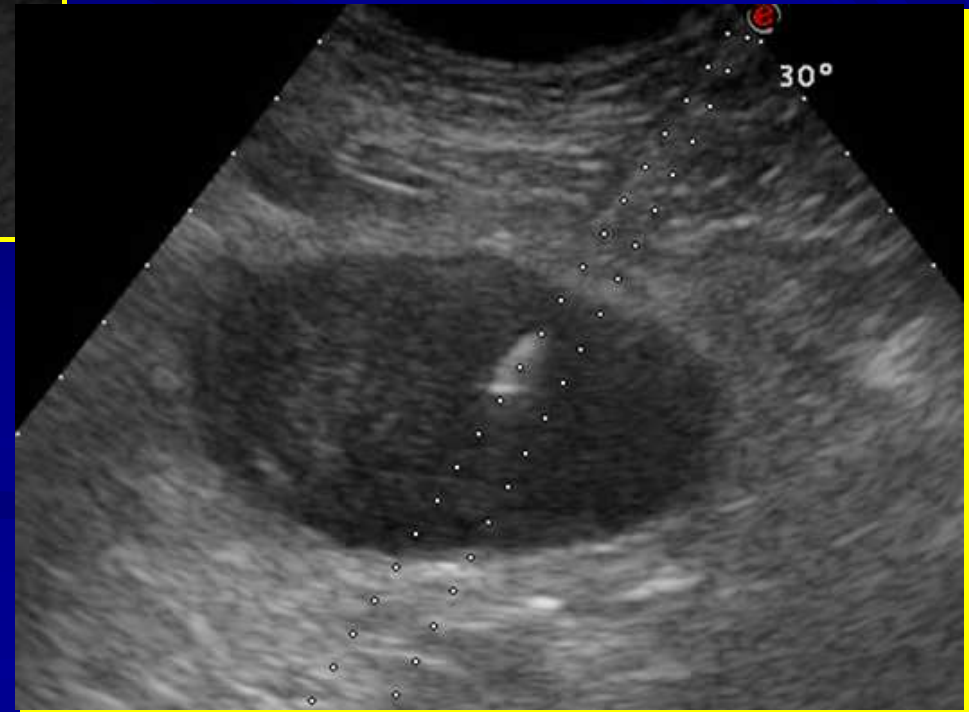
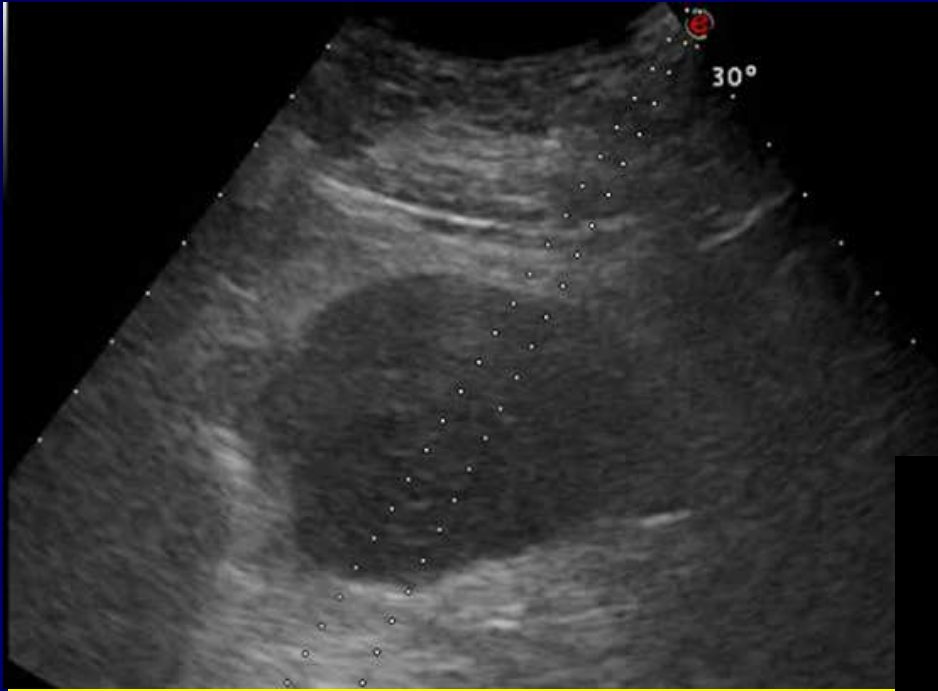
***Raccolta!***



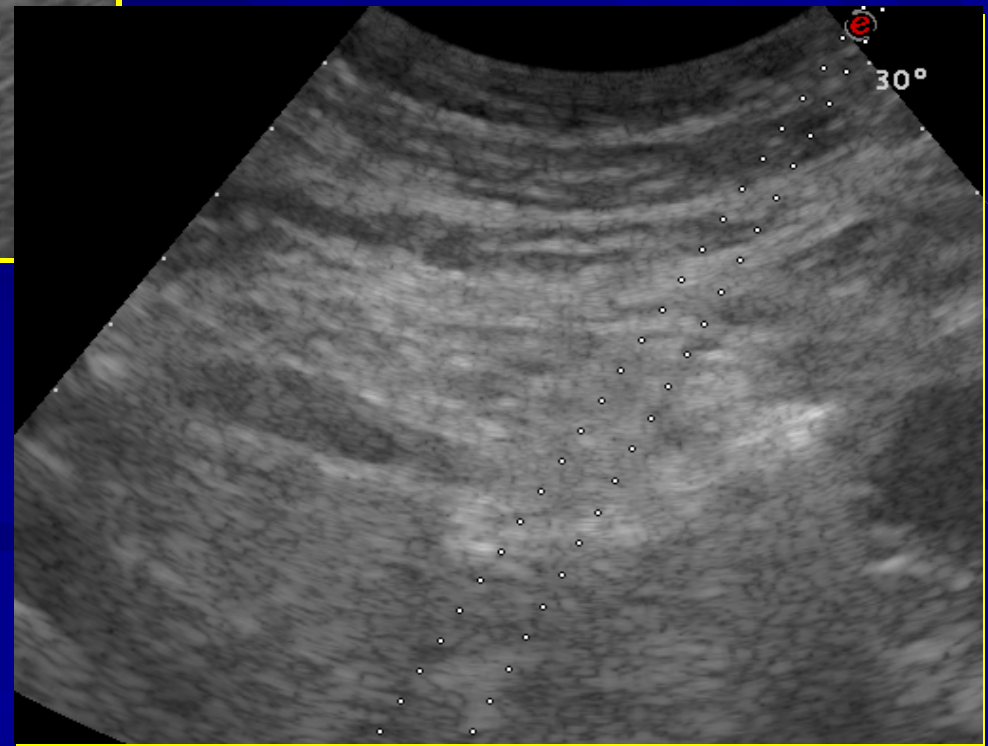
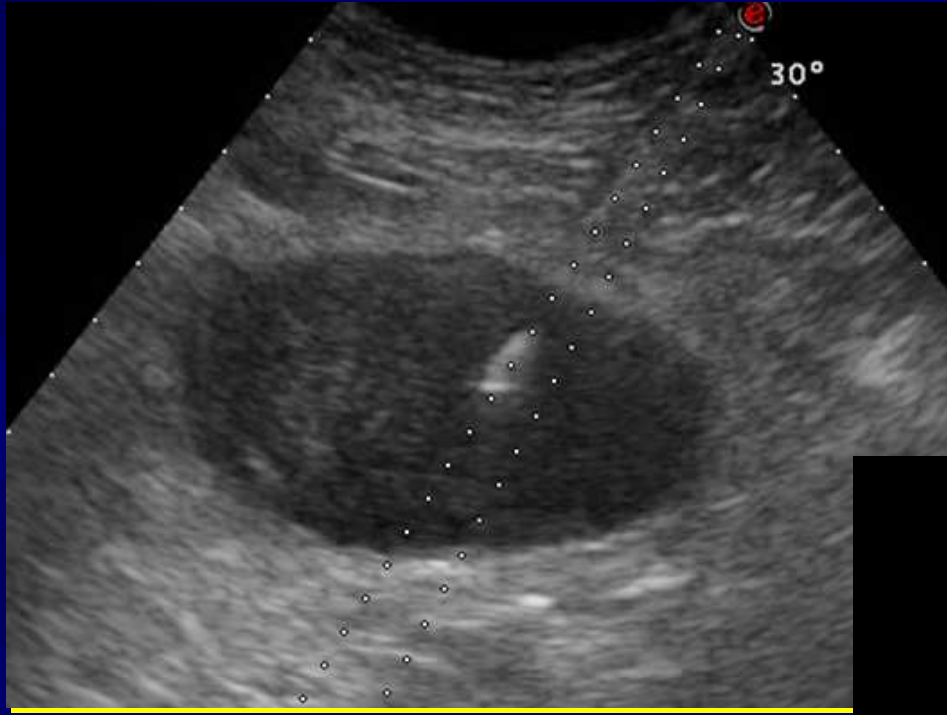
# TERAPIA



# TERAPIA



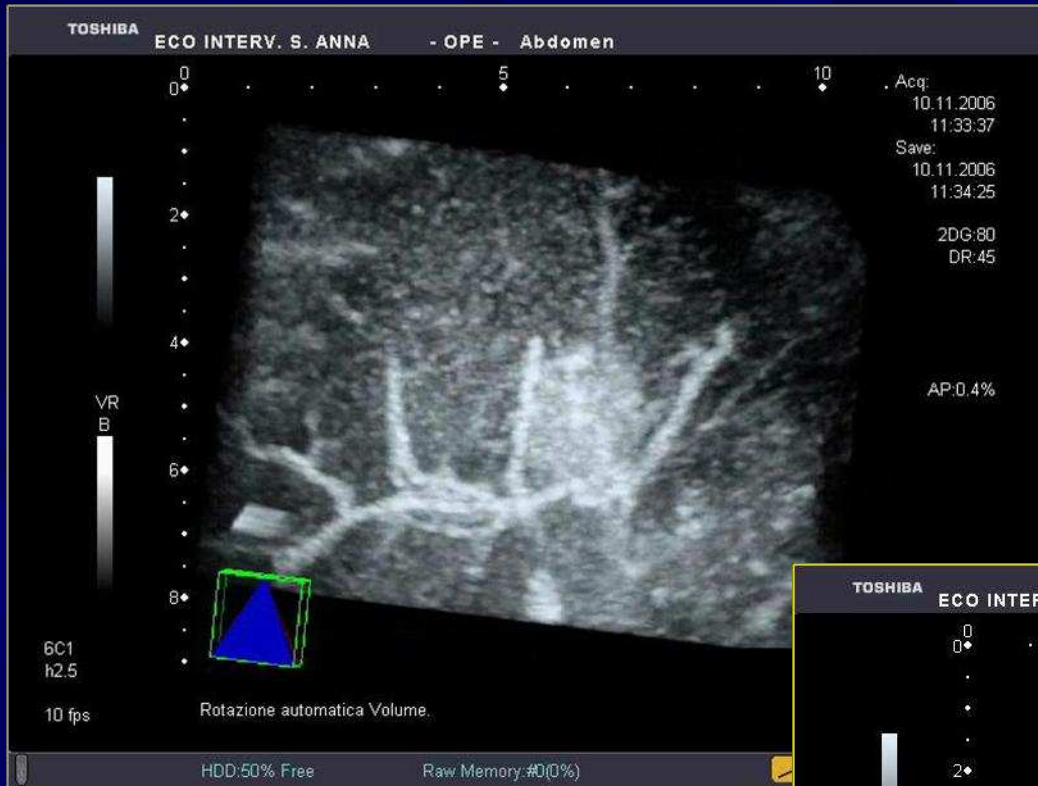
# ***FOLLOW-UP***



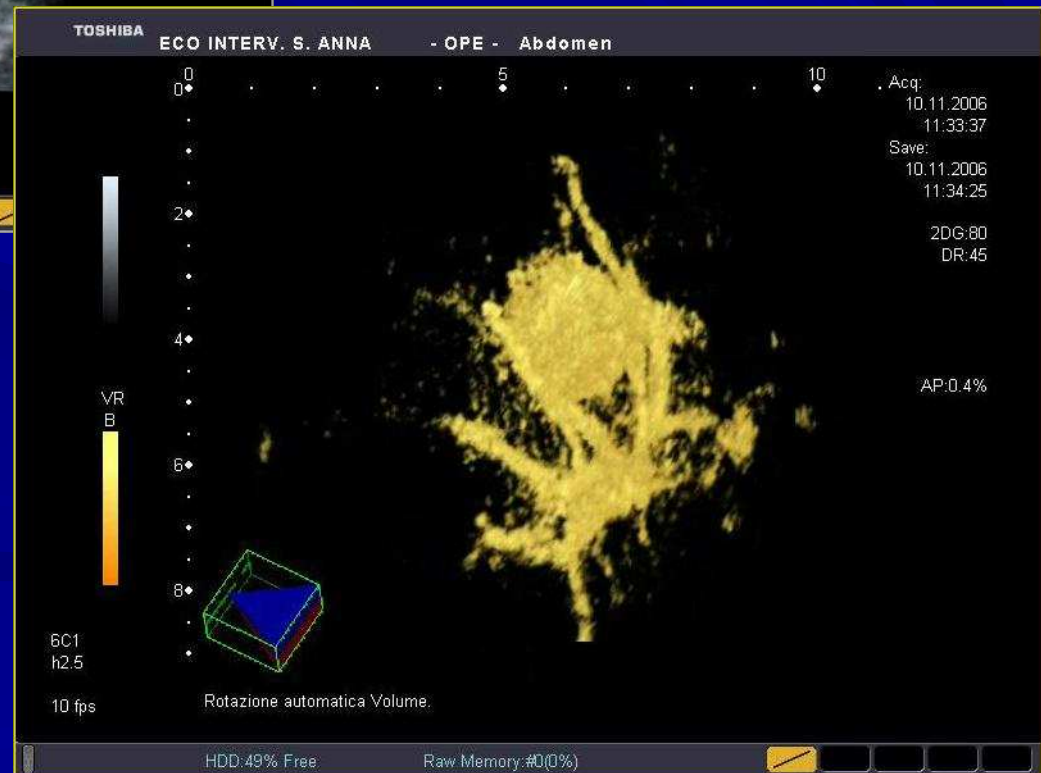
# ***CINDERELLA FOREVER?***



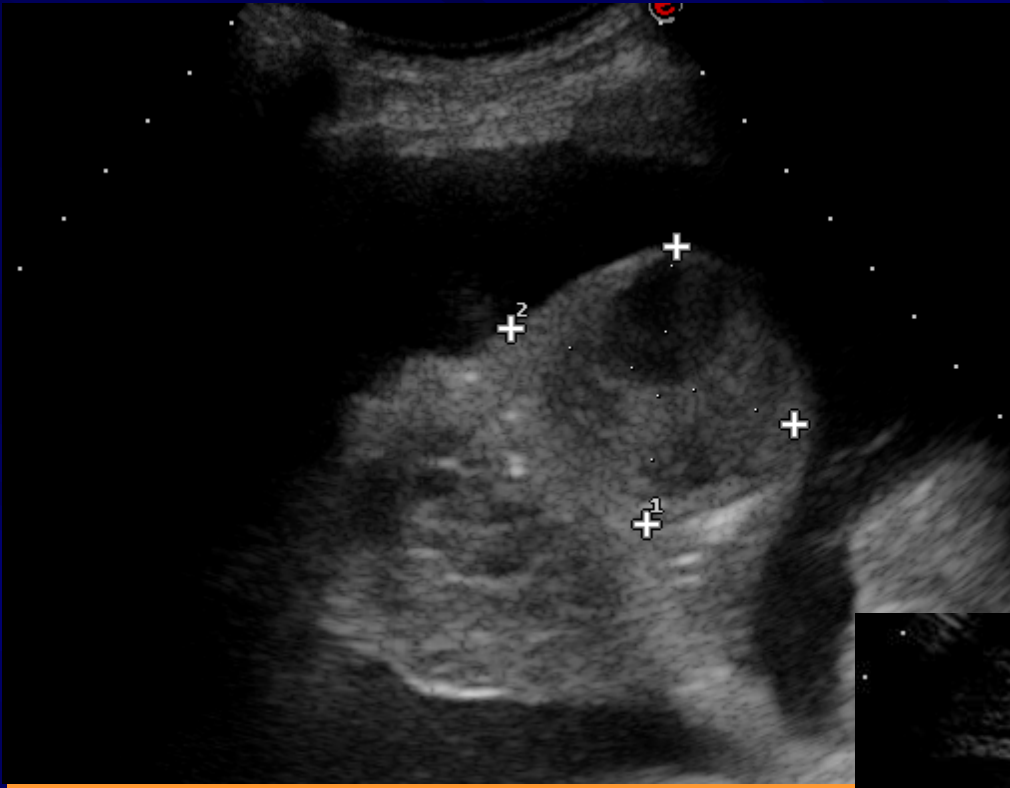
**M.d.C.**



**3 D**



***Polmonite  
ascessualizzata?***



***M.d.C.: polmonite  
ascessualizzata***

