

**AGGIORNAMENTI  
NELL'APPROCCIO  
DIAGNOSTICO-TERAPEUTICO  
AI TUMORI NEUROENDOCRINI  
GASTRO-ENTERO-PANCREATICI**

**Sabato 18 maggio 2013**

**SERGIO GULLINI**

# Oberndorfer S. Karzinoide Tumouren des Dunndarms. Frankf Z Pathol. 1907;1:425-9



Zhonghua Zhong Liu Za Zhi. 2013 Jan;35(1):67-70.

**[Neuroendocrine tumors: analysis of 252 cases].**

**CONCLUSIONS:** This single-center retrospective analysis of data demonstrated that males have a higher incidence rate than females. The most common primary sites of NETs are the digestive tract and lungs. The initial symptoms of NETs are different depending on their primary sites. Good prognosis can be achieved in the majority of patients after surgery, chemotherapy and palliative radiotherapy.

# TUMORI NEUROENDOCRINI

- ORIGINANO DA CELLULE DEL SISTEMA NEUROENDOCRINO DIFFUSO, CHE COMPRENDE CELLULE SPARSE IN NUMEROSI ORGANI E TESSUTI CHE PRODUCONO VARIE SOSTANZE ORMONALI.
- GRUPPO ETEROGENEO DI TUMORI .
- UBIQUITARI, MA PIU' FREQUENTI IN AMBITO INTESTINALE E TORACICO .
- POSSONO ESSERE SPORADICI O NEL CONTESTO DI NEOPLASIE ENDOCRINE MULTIPLE GENETICAMENTE TRASMESSE ( MEN) .
- SI POSSONO SUDDIVIDERE IN FUNZIONANTI O NON FUNZIONANTI .
- QUELLI FUNZIONANTI, HANNO CARATTERISTICHE BIOLOGICHE UTILI PER LA DIAGNOSI, TERAPIA E FOLLOW-UP .
- I SINTOMI PRINCIPALI SONO VARI E IN GENERE, DIPENDONO DA SEDE E CARATTERISTICHE DEL TUMORE .

## Gastrointestinal neuroendocrine tumours

### Functioning neuroendocrine tumours

#### Carcinoid

Flushing, diarrhoea, and wheezing

### Non-functioning neuroendocrine tumours

Abdominal pain, weight loss, anorexia, jaundice, nausea and vomiting, intra-abdominal haemorrhage

## Pancreatic neuroendocrine tumours

### Functioning neuroendocrine tumours

#### Insulinoma

Neuroglycopenic symptoms such as headache, blurred vision, confusion, dizziness, lethargy, and amnesia. Autonomic nervous system symptoms such as sweating, weakness, anxiety, tremor, palpitations, and nausea

#### Gastrinoma

Diarrhoea, abdominal pain, heartburn, weight loss, nausea and vomiting, faecal blood loss

#### Glucagonoma

Necrolytic migratory erythema, diabetes mellitus, cachexia

#### VIPoma

Watery diarrhoea, hypokalaemia, achlorhydria, hyperglycaemia, hypercalcaemia, flushing

#### Somatostatinoma

Diabetes mellitus, cholelithiasis, steatorrhoea, anaemia, weight loss

### Other (rare) pancreatic functioning neuroendocrine tumours

#### ACTHoma

Cushing's syndrome

#### GRFoma

Acromegaly

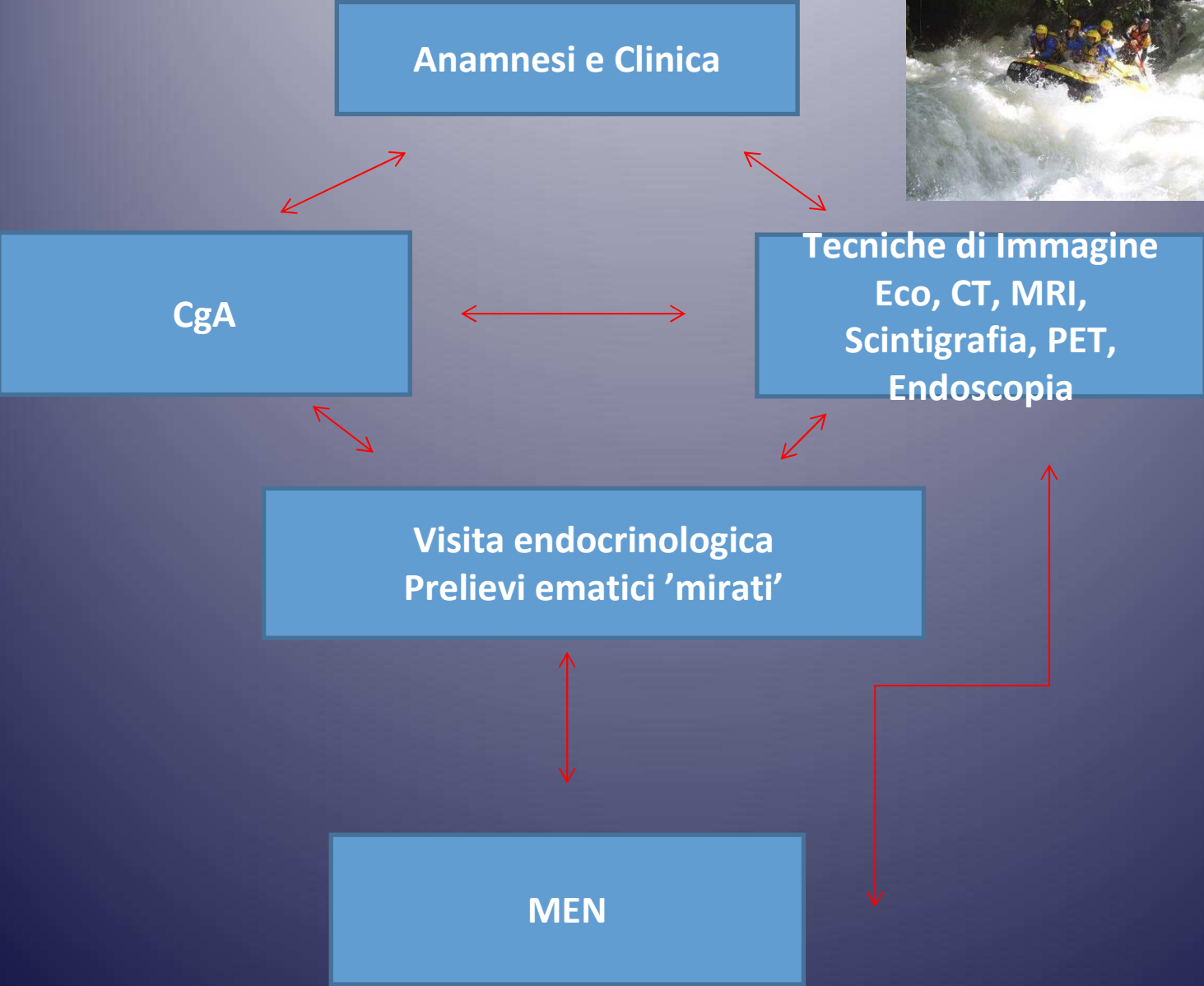
#### PTH-RP tumour

Hypercalcaemia

Netherlands  
The Journal of Medicine  
JANUARY 2011, VOL. 69, NO 1  
REVIEW

## An overview of the current diagnosis and recent developments in neuroendocrine tumours of the gastroenteropancreatic tract: the diagnostic approach

P. Kuiper<sup>\*</sup>, H.W. Verspaget<sup>†</sup>, L.I.H. Overbeek<sup>‡</sup>, I. Biemond<sup>§</sup>, C.B. Lamers<sup>¶</sup>



Endoscopy. 2008 Jun;40(6):488-95. doi: 10.1055/s-2007-995783. Epub 2008 May 8.

## Small-bowel neoplasms in patients undergoing video capsule endoscopy: a multicenter European study.

Rondonotti E, Pennazio M, Toth E, Menchen P, Riccioni ME, De Palma GD, Scotti F, De Looze D, Pachofsky T, Tacheci I, Havelund T, Couto G, Trifan A, Kofokotsios A, Cannizzaro R, Perez-Quadrado E, de Franchis R; European Capsule Endoscopy Group; Italian Club for Capsule Endoscopy (CICE); Iberian Group for Capsule Endoscopy.

### + Collaborators (13)

Università degli Studi di Milano, IRCCS Fondazione Policlinico, Mangiagalli, Regina Elena Dipartimento di Scienze Mediche, Unità Operativa Gastroenterologia 3, 20122 Milano, Italy  
emanuele.rondonotti@unimi.it

### Abstract

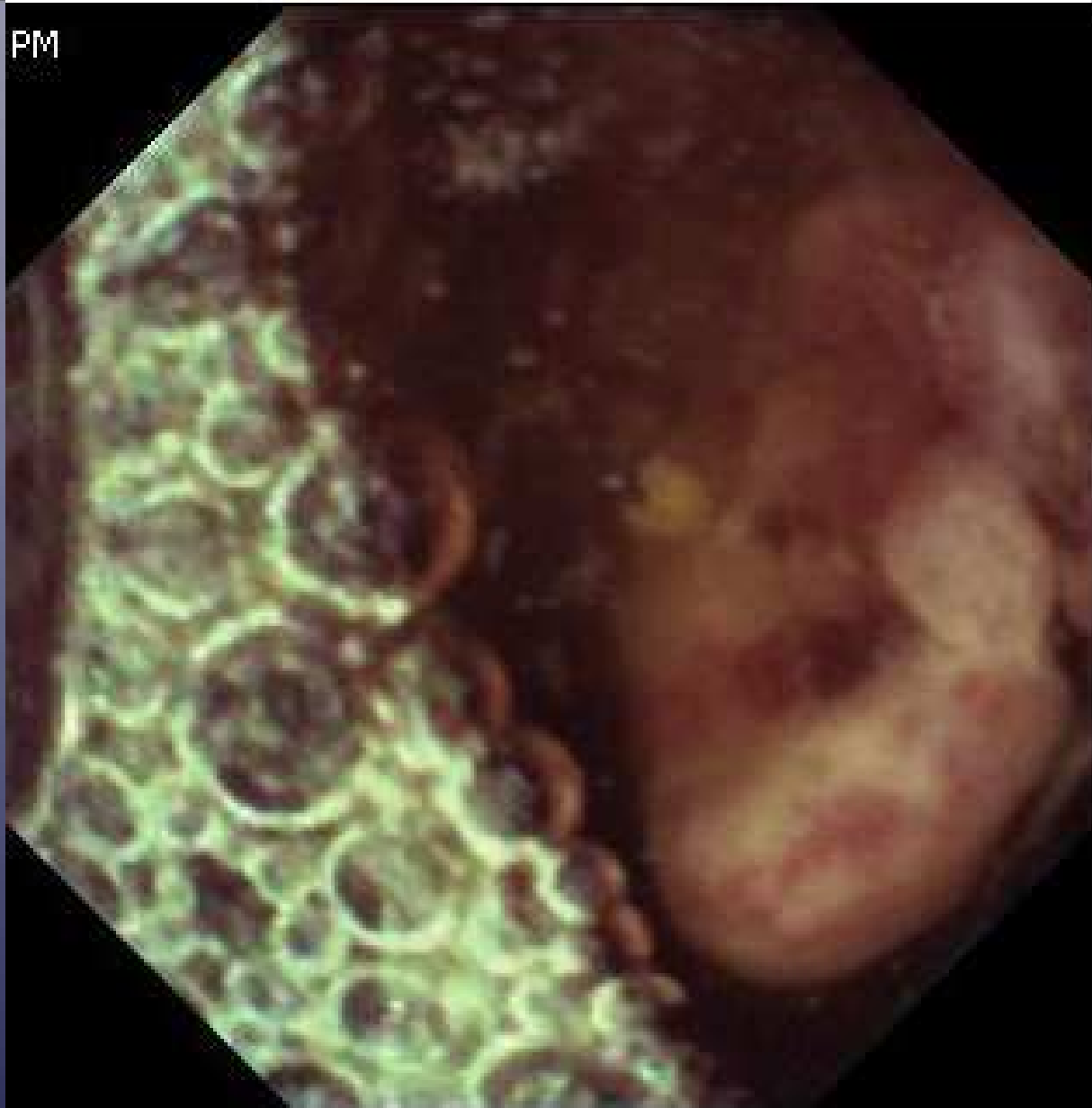**BACKGROUND AND STUDY AIM:** Small-bowel tumors account for 1% - 3% of all gastrointestinal neoplasms. Recent studies with video capsule endoscopy (VCE) suggest that the frequency of these tumors may be substantially higher than previously reported. The aim of the study was to evaluate the frequency, clinical presentation, diagnostic/therapeutic work-up, and endoscopic appearance of small-bowel tumors in a large population of patients undergoing VCE.

**PATIENTS AND METHODS:** Identification by a questionnaire of patients with VCE findings suggesting small-bowel tumors and histological confirmation of the neoplasm seen in 29 centers of 10 European Countries.

**RESULTS:** Of 5129 patients undergoing VCE, 124 (2.4%) had small-bowel tumors (112 primary, 12 metastatic). Among these patients, indications for VCE were: obscure gastrointestinal bleeding (108 patients), abdominal pain (9), search for primary neoplasm (6), diarrhea with malabsorption (1). The main primary small-bowel tumor type was gastrointestinal stromal tumor (GIST) (32%) followed by adenocarcinoma (20%) and carcinoid (15%); 66% of secondary small-bowel tumors were melanomas. Of the tumors, 80.6% were identified solely on the basis of VCE findings. 55 patients underwent VCE as the third procedure after negative bidirectional endoscopy. The lesions were single in 89.5% of cases, and multiple in 10.5%. Retention of the capsule occurred in 9.8% of patients with small-bowel tumors. After VCE, 54/124 patients underwent 57 other examinations before treatment; in these patients enteroscopy, when performed, showed a high diagnostic yield. Treatment was surgery in 95% of cases.

**CONCLUSIONS:** Our data suggest that VCE detects small-bowel tumors in a small proportion of patients undergoing this examination, but the early use of this tool can shorten the diagnostic work-up and influence the subsequent management of these patients.

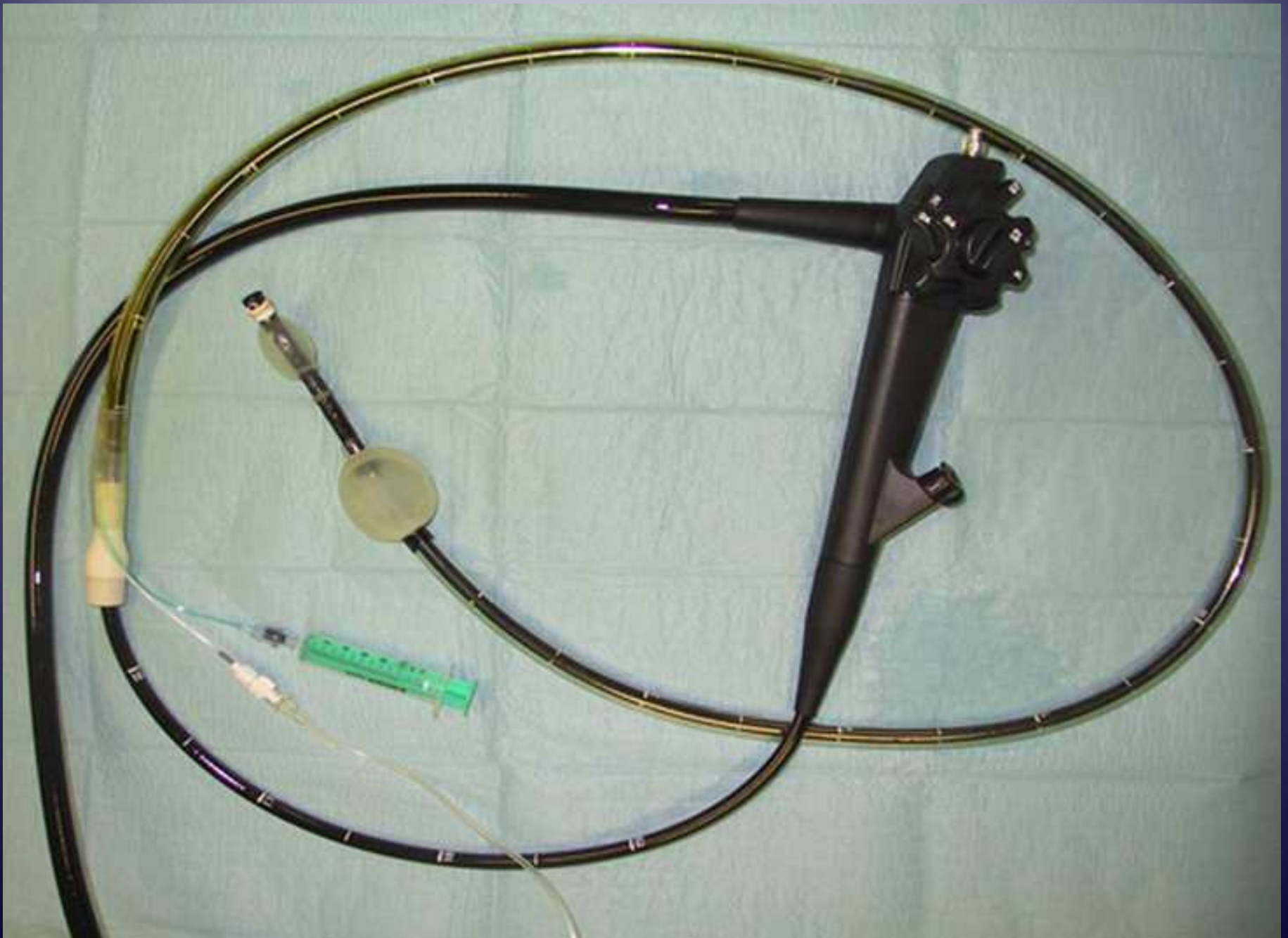PM



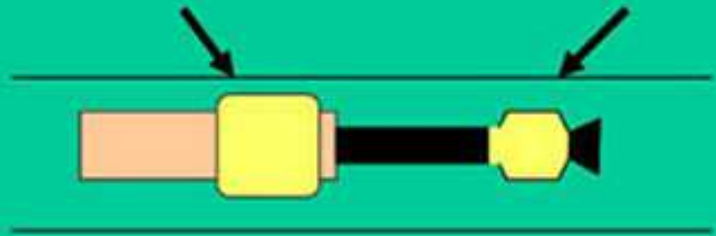
IntroMedicçs

09 Sep 2009 08:41:42

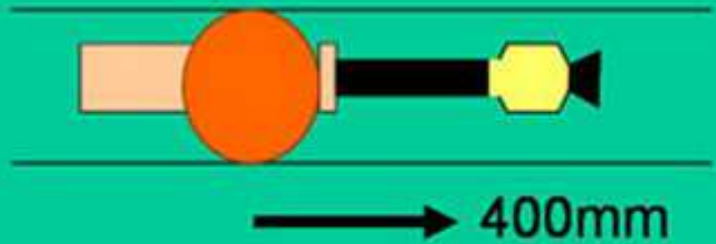
Tumore neuroendocrino ileale



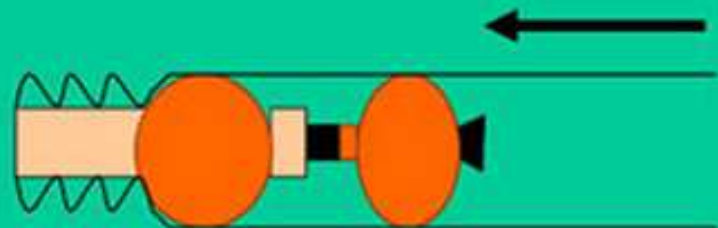


• **Overtube**                      **Endoscope**



• **Overtube**                      **Endoscope**



• **Overtube**                      **Endoscope**



• **Overtube**                      **Endoscope**

