

# Approccio Integrato e Multidisciplinare nella Patologia dell'Articolazione Temporomandibolare

## La Terapia Chirurgica nei Disordini Temporo Mandibolari

**Stefano Mandrioli**

*U.O. Chirurgia Maxillo Facciale  
AOU Arcispedale S. Anna, Ferrara  
(Direttore: Dr. M. Galì)*



Sabato 23 novembre 2019  
dalle ore 8.30 alle 13.30  
Aula Magna  
Nuovo Ospedale S. Anna  
Cona - Ferrara




**-La decisione di sottoporre un paziente con DTM  
ad intervento chirurgico  
è un processo decisionale complesso**

**5%**


**La chirurgia **NON** è l'*ultima spiaggia* ma una  
possibilità terapeutica**

**- Valutazione corretta dei sintomi**



***maggior parte dei pazienti ha forme miste  
muscolari/articolari***

## Diagnostica per immagini



***ruolo di supporto***


**frequente la presenza di dislocazioni del disco  
articolare e degenerazione condilare  
in pazienti asintomatici**



## Quando?

- fallimento delle precedenti strategie terapeutiche (oral devices, terapia medica, comportamentale, fisioterapia...)

### - DOLORE/IMPOTENZA FUNZIONALE




### danno articolare

- closed lock acuto

- *malattie reumatologiche*: artrite reumatoide, artrite idiopatica giovanile, fibromialgia (sovraccarico muscolare sulle articolazioni), artrosi, condrocalcinosi, condromatosi
  - malformazioni: anchilosi e reanchilosi
- *tumori*: benigni (condroma, osteoma)/maligni (sarcomi)

### SINTOMATOLOGIA MUSCOLARE



**NO CHIRURGIA**



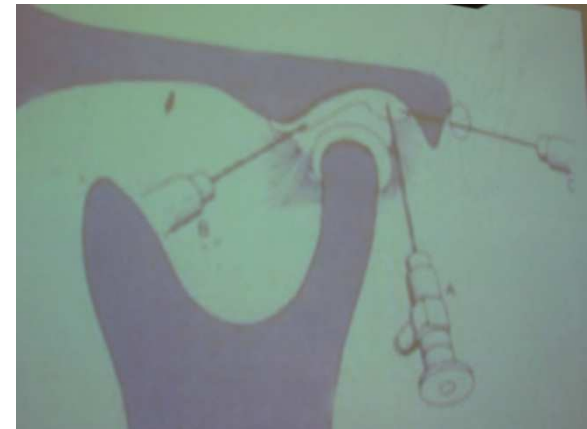
# TECNICHE:

- *Artrocentesi*
- *Artroscopia*
- *Chirurgia open*



# ARTROCENTESI:

- *Lisi e lavaggio delle aderenze e del materiale infiammatorio*
  - An locale con sedazione  
*(Mono) - Bilaterale*
    - Due aghi 19
  - *Ringer lattato ( 100-250 cc per lato )*
    - Anestetico locale intracapsulare
  - *Ac ialuronico intracapsulare al termine*
    - *Mobilizzazione precoce*
      - Bite

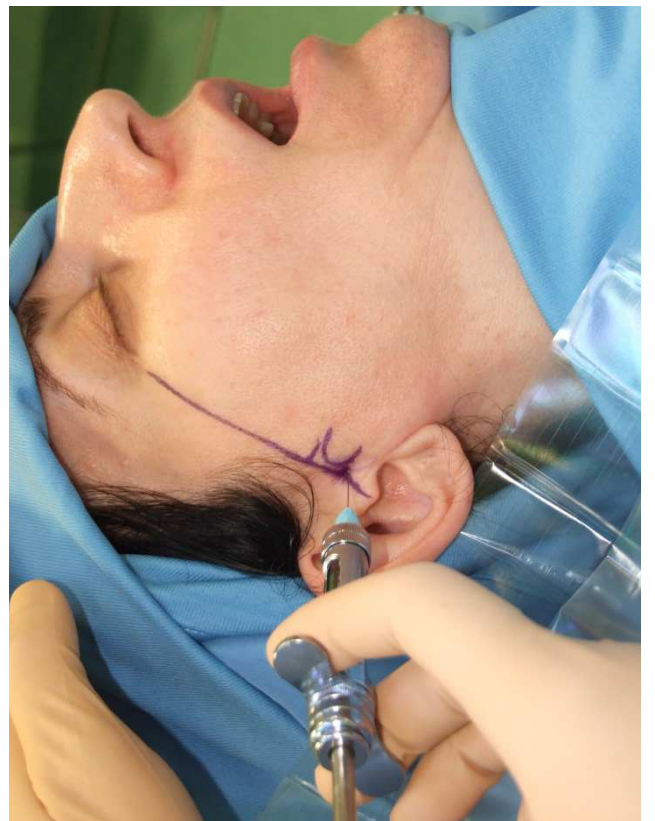
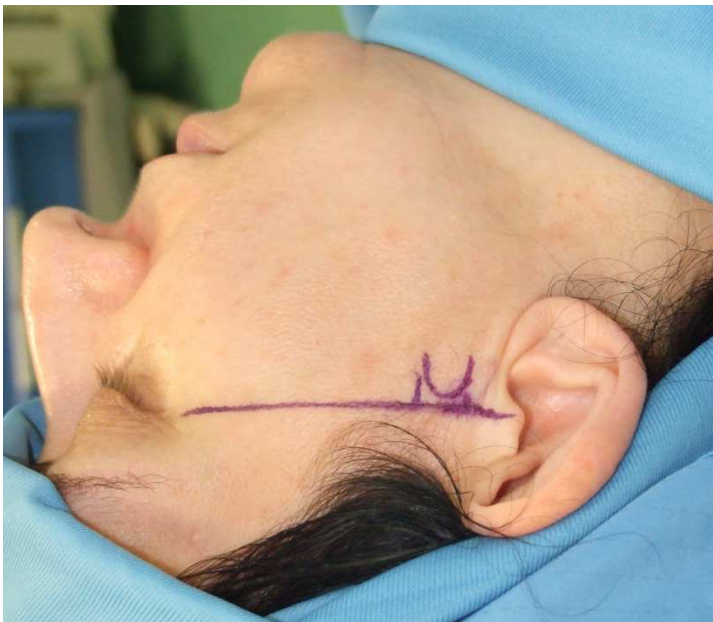
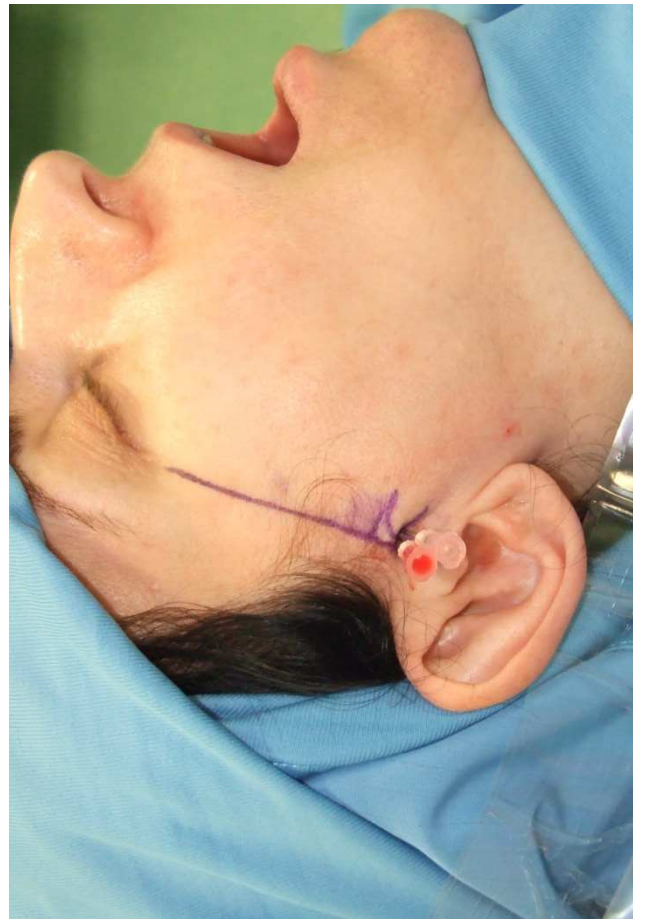
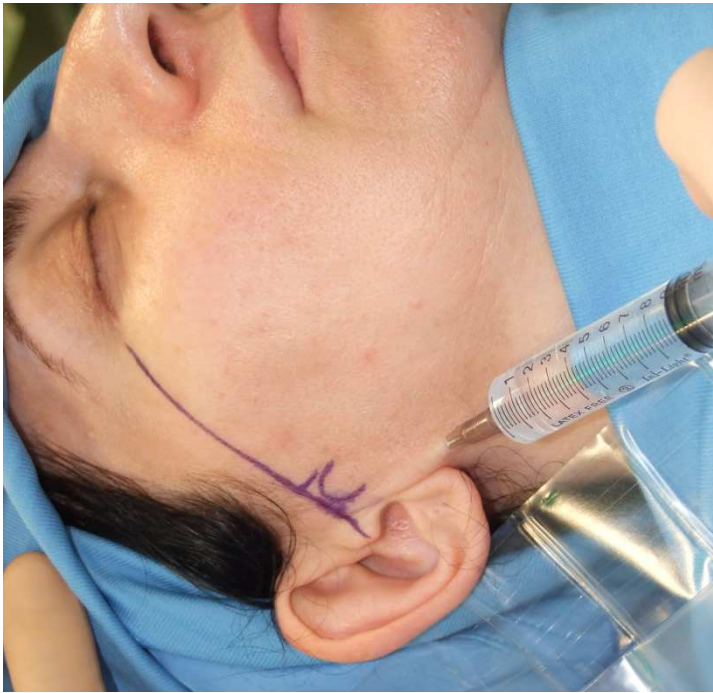
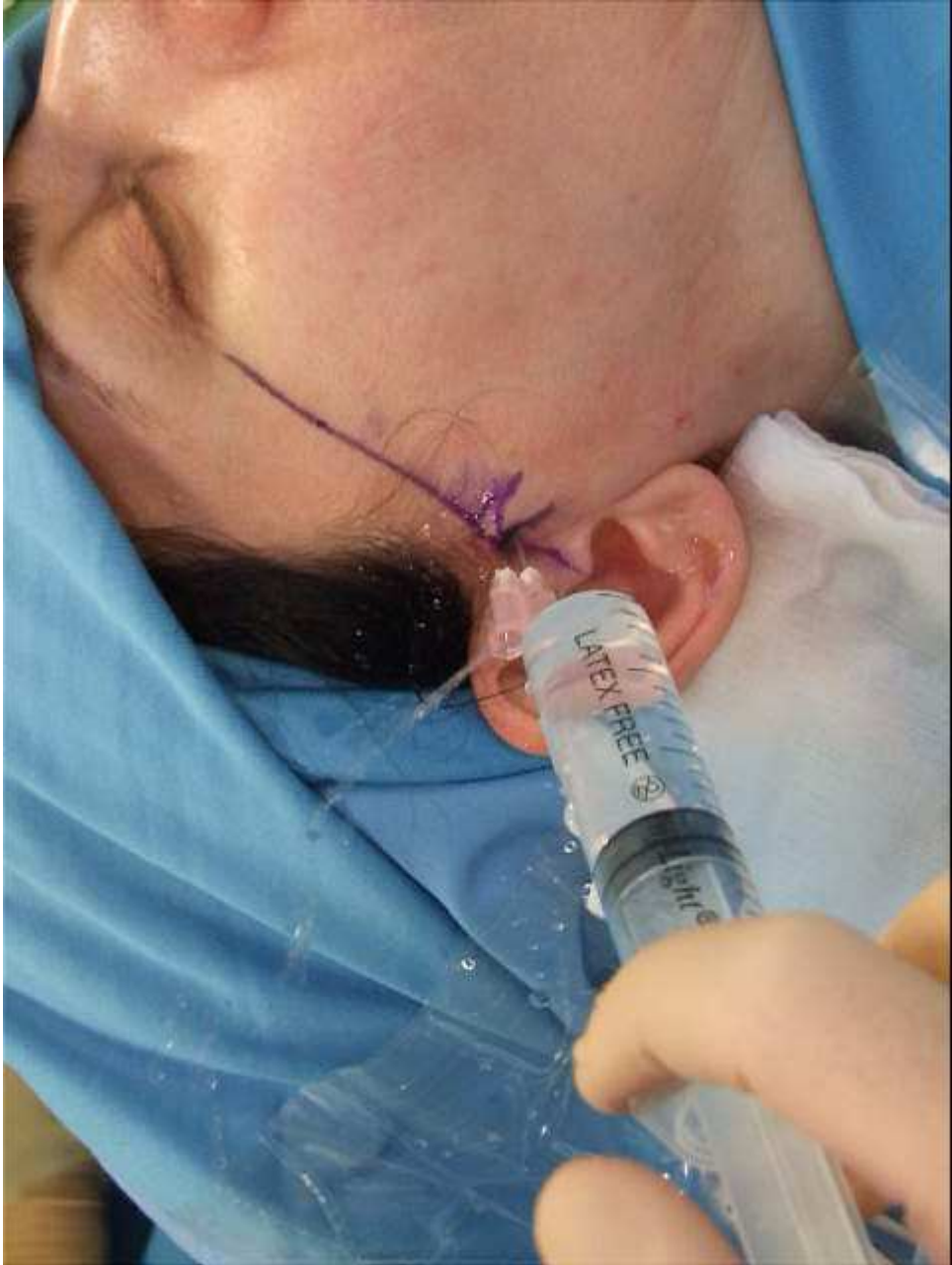## **Vantaggi:**

- ***Immediata, con ripristino della motilità mandibolare e netta riduzione del dolore***
- ***Rapida, economica, poche complicanze (difficoltà all'occlusione, stupor facciale, ovattamento auricolare) e tutte temporanee***
- ***Ripetibile***
- ***An locale***
- ***Efficacia***

## **Svantaggi:**

- ***Empirica***
- ***Non visibilità della camera articolare***
- ***Lieve disagio del paziente***





## ACIDO IALURONICO:

- Trattamento visco-suppletivo come sostituto del liquido sinoviale per il ripristino delle proprietà fisiologiche delle articolazioni artrosiche
- *Riduce il dolore e ripristina la mobilità articolare*
- 0,8% 8mg /1 ml

# **ARTROSCOPIA:**

***Lisi e lavaggio delle aderenze e del materiale  
infiammatorio***

**-Narcosi**

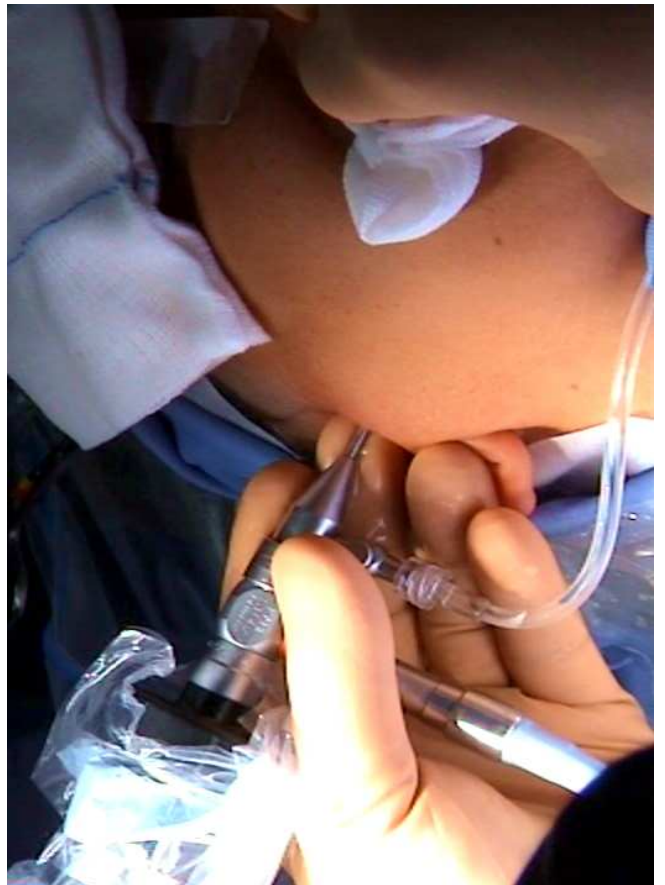
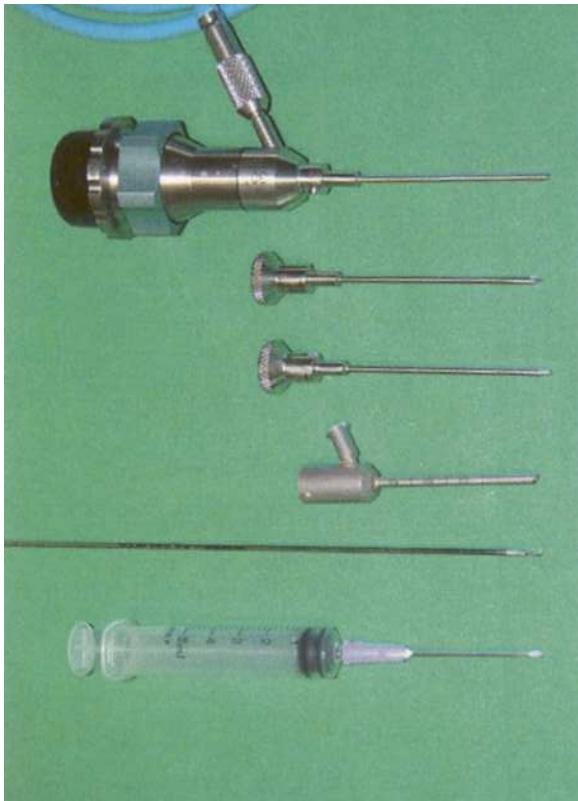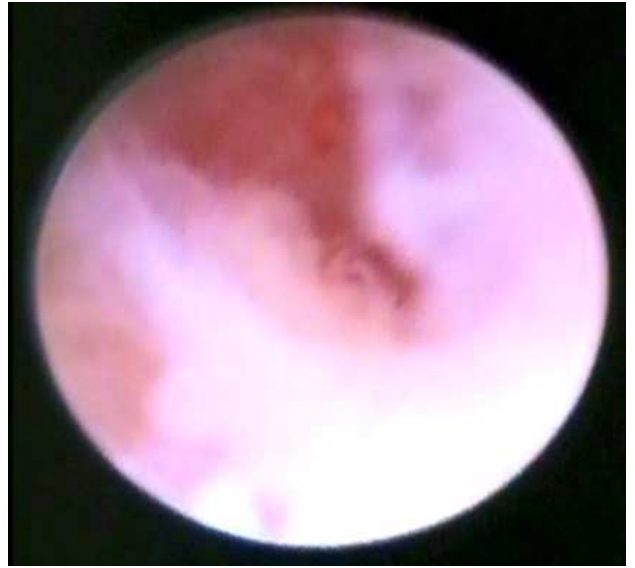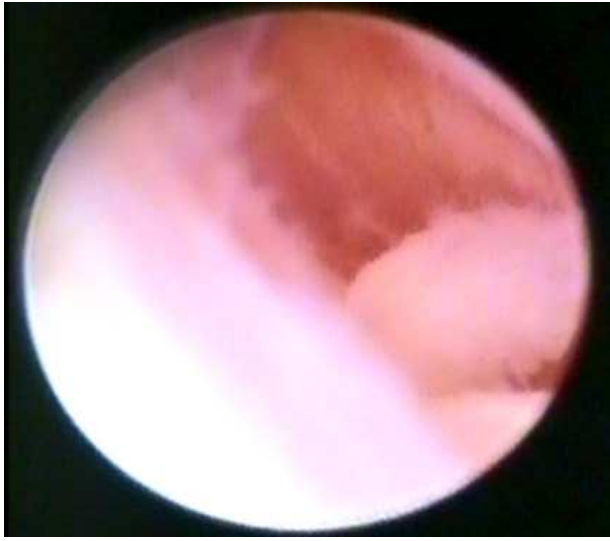***-Chirurgia dell'articolazione (riposizionamento  
discale, ultrasuoni, cauterizzazione, ecc )***

## **Vantaggi:**

- **Visione diretta ingrandita**
- ***Possibilità di chirurgia***
- **Ripetibile**
- ***Poche complicanze***

## **Svantaggi:**

- **Narcosi**
- ***Costosa***
- **Alta curva di apprendimento per il chirurgo**



## ARTROPLASTICA:

-Chirurgia a cielo aperto

-*Via preauricolare*

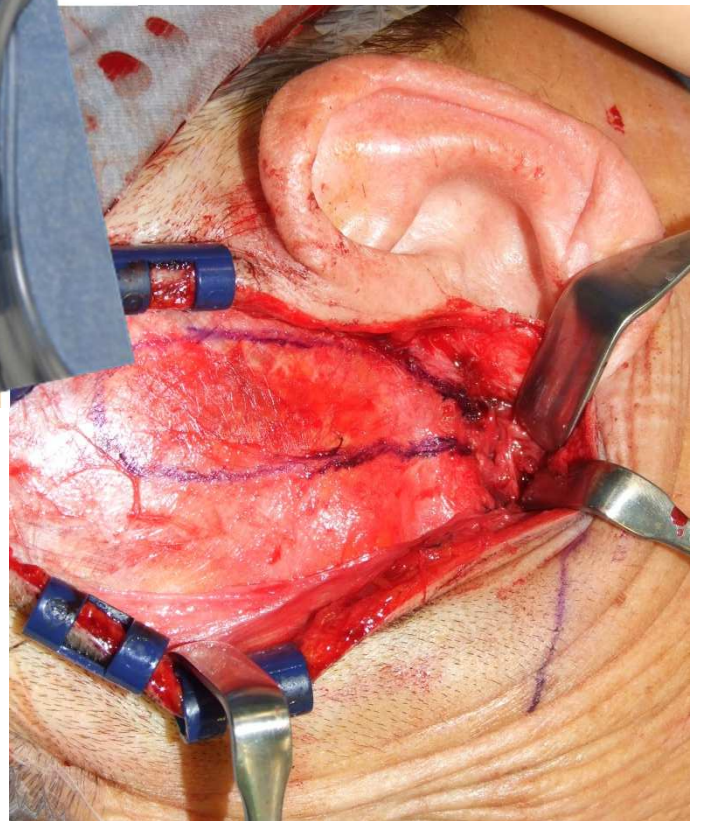
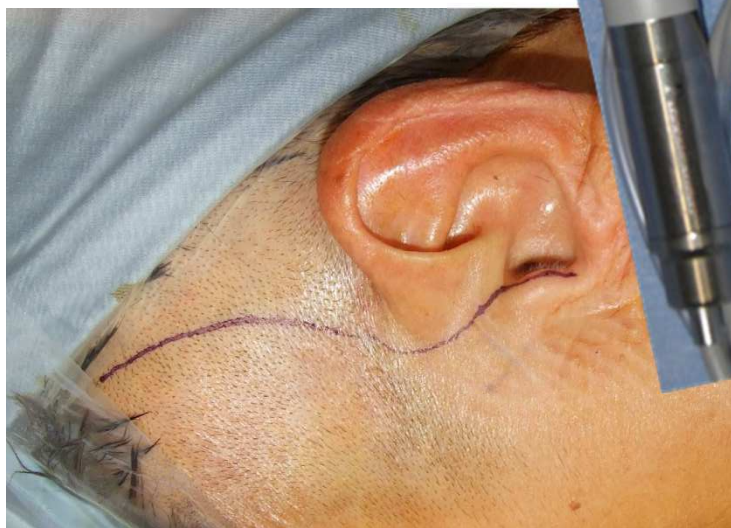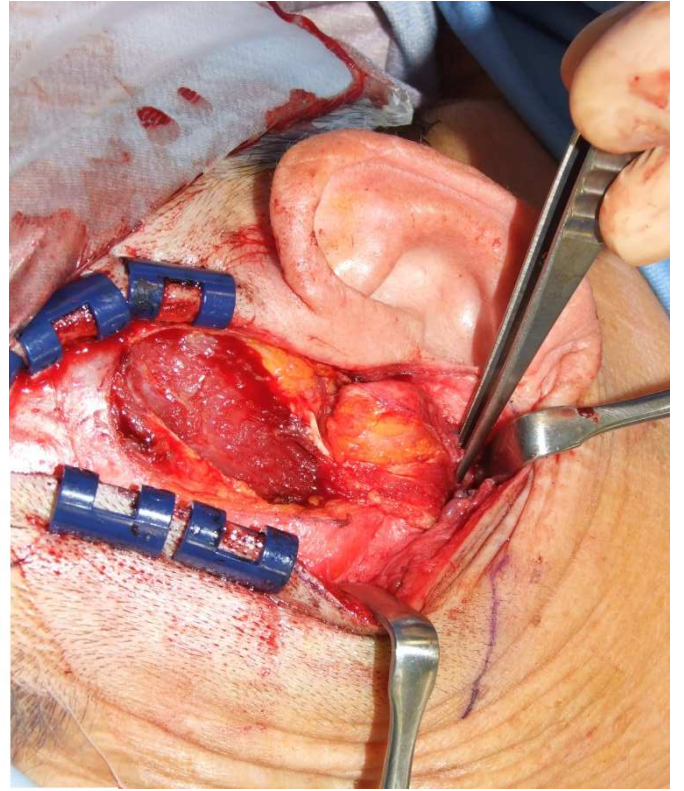
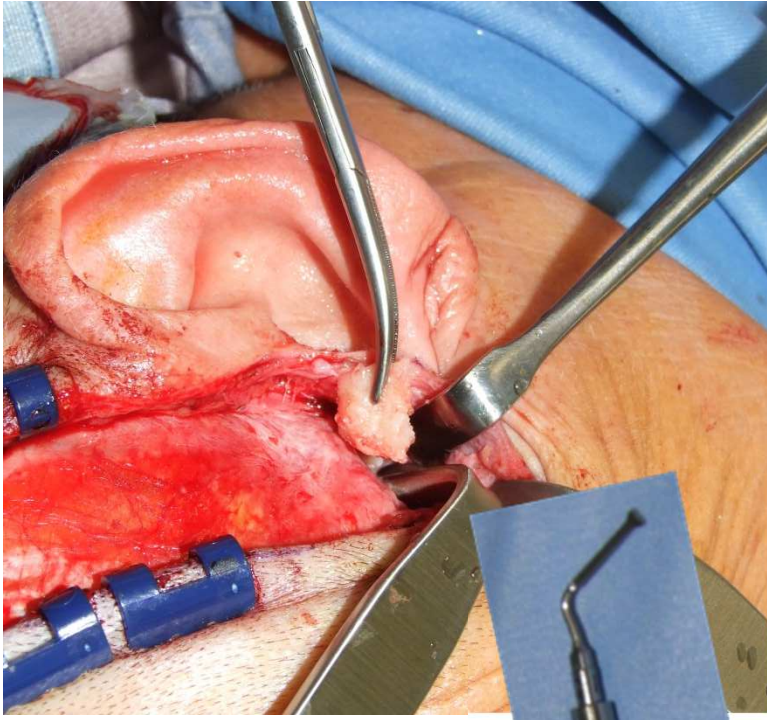
-**Condylar shaving** con riposizionamento del disco articolare, sua sostituzione, rimodellamento della testa del condilo, eventuale trasposizione di lembo di muscolo temporale

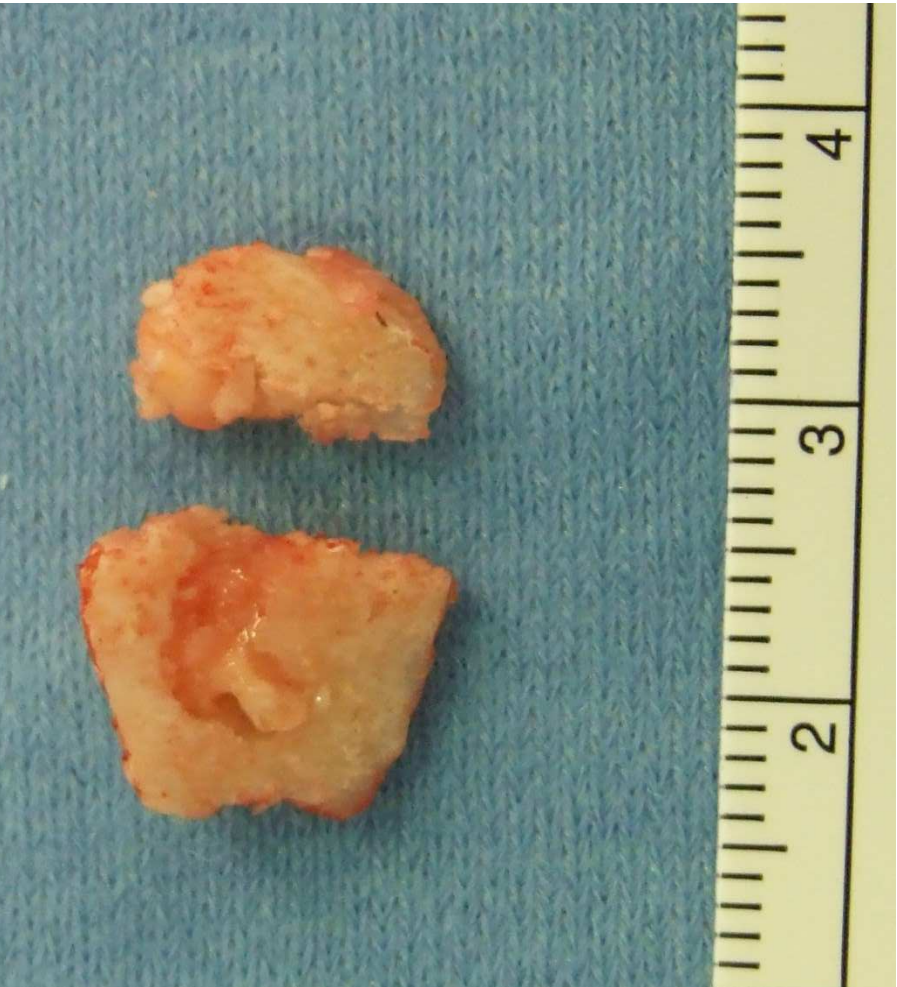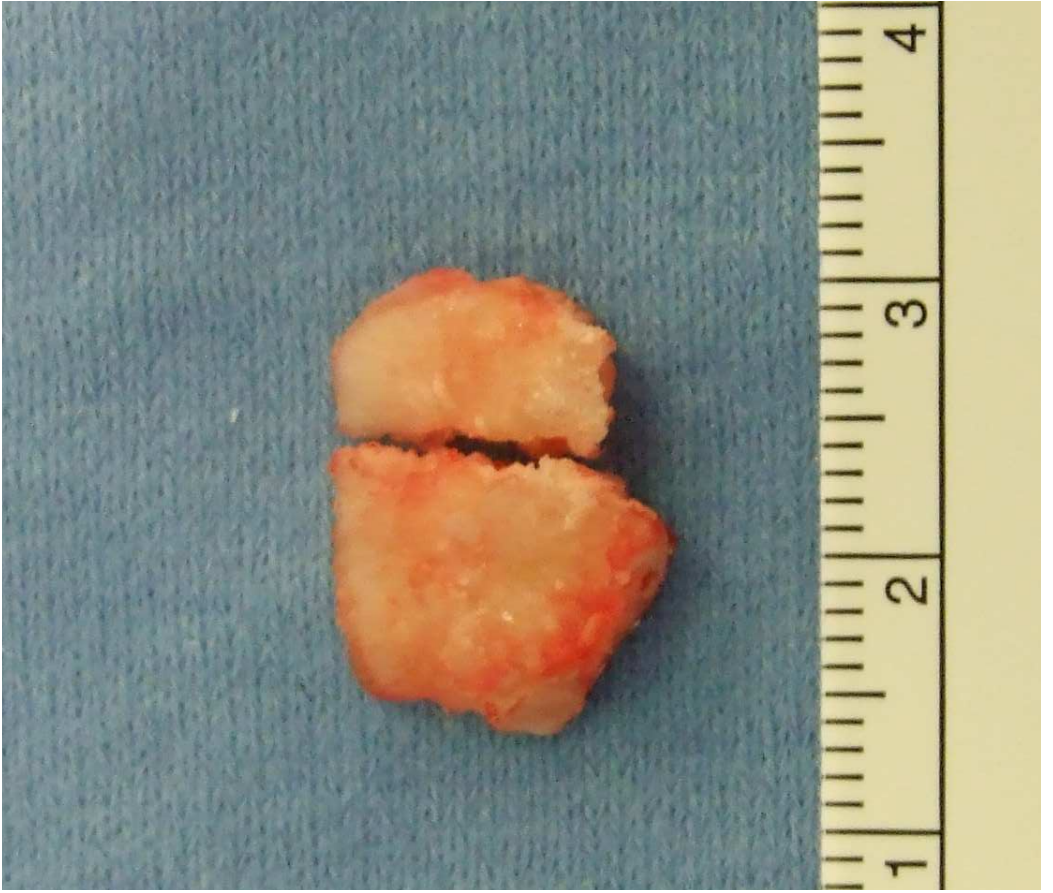## **VANTAGGI:**

- Ampio campo operatorio
- *Rapido risultato in termini di risoluzione del dolore e della funzionalità, stabile nel tempo*
- Chirurgia con ampia % di successo **(72-85%)**

## **SVANTAGGI:**

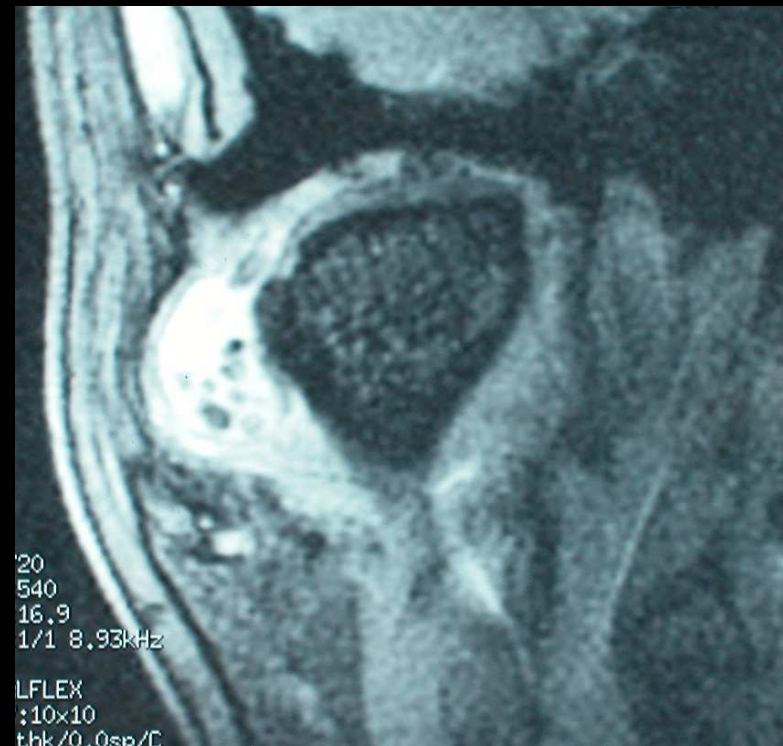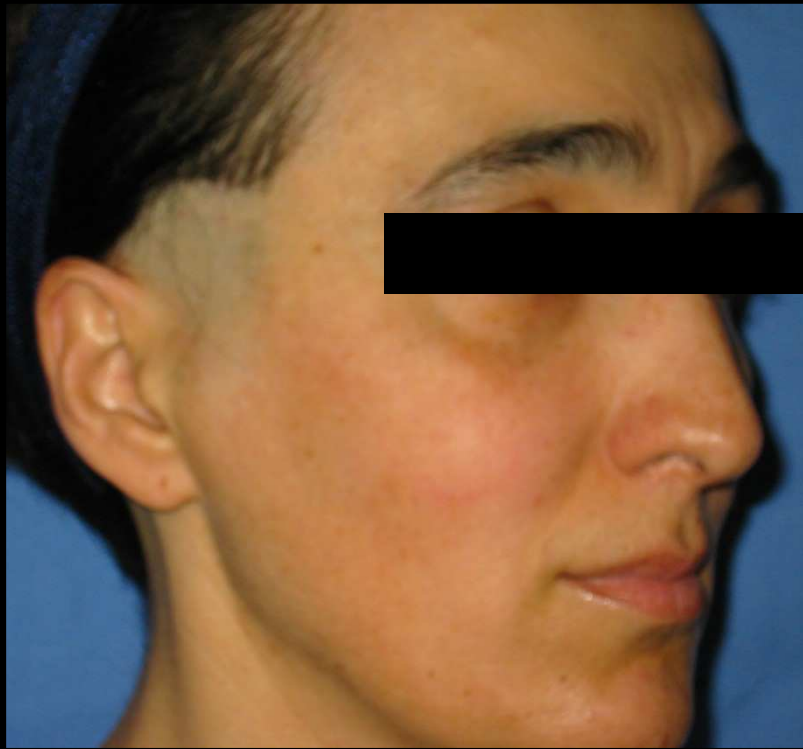- Narcosi
- *Rischio danno del nervo facciale*
- Cicatrici
- *Anchilosi*

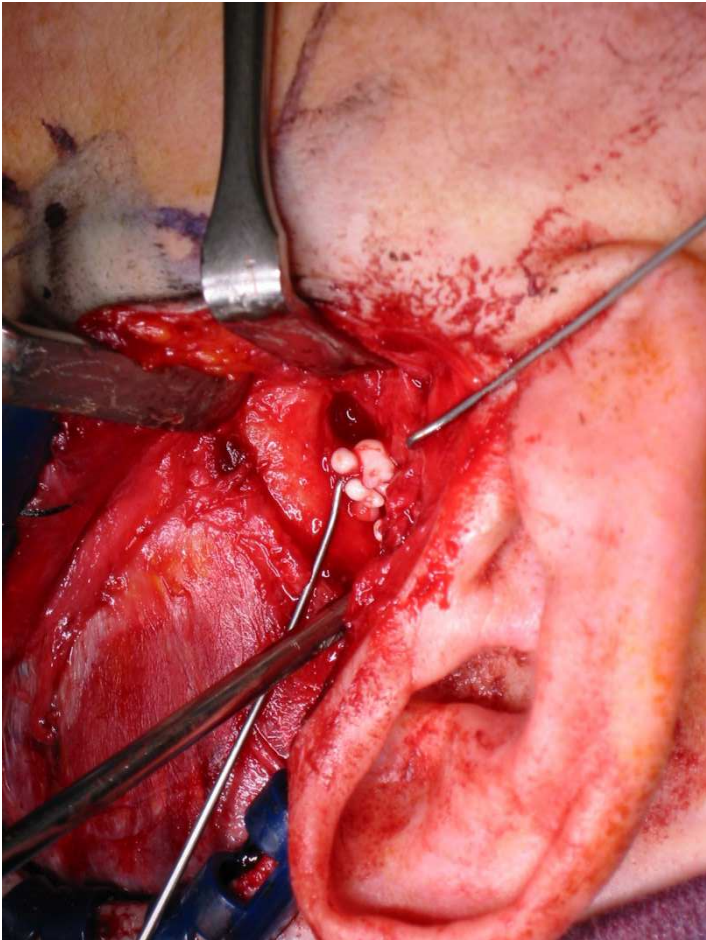
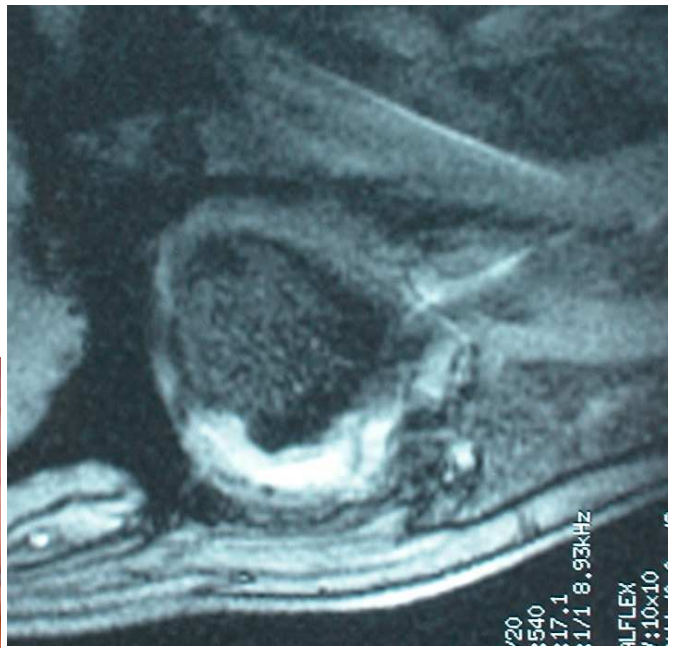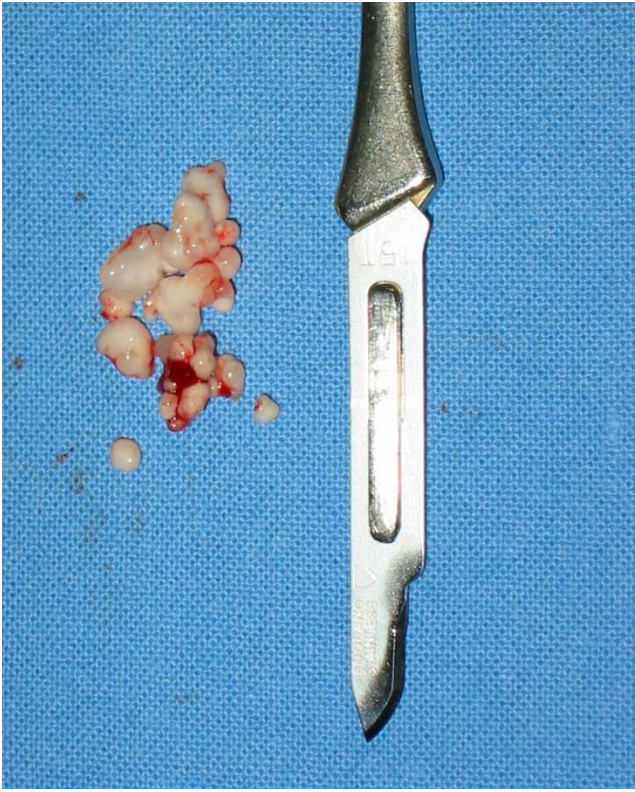




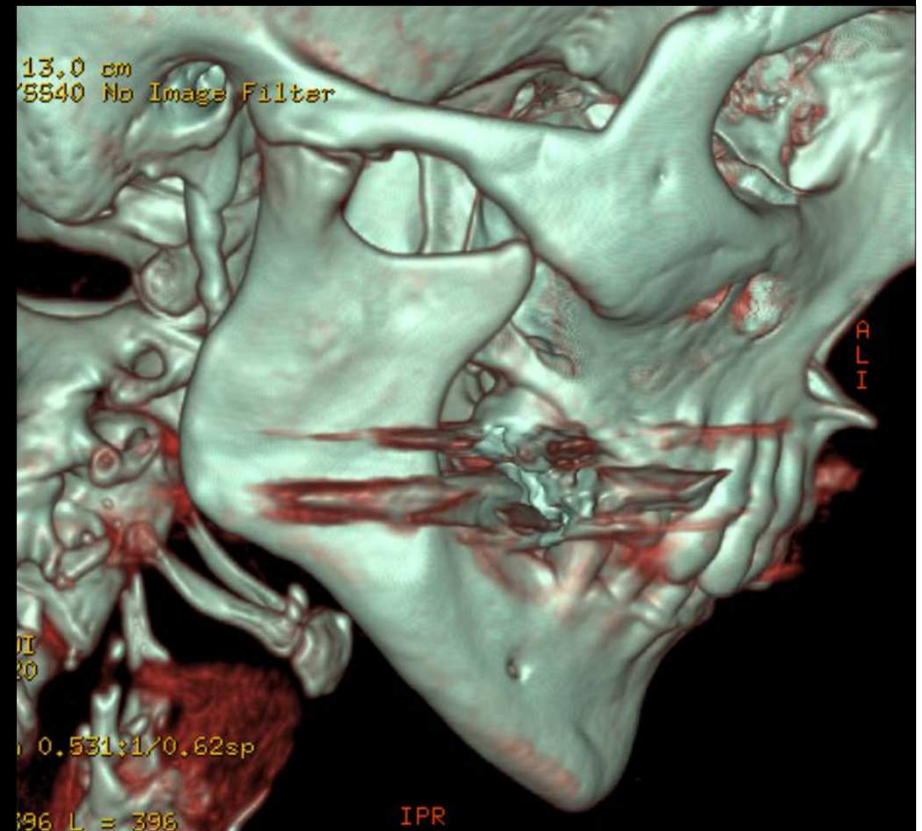

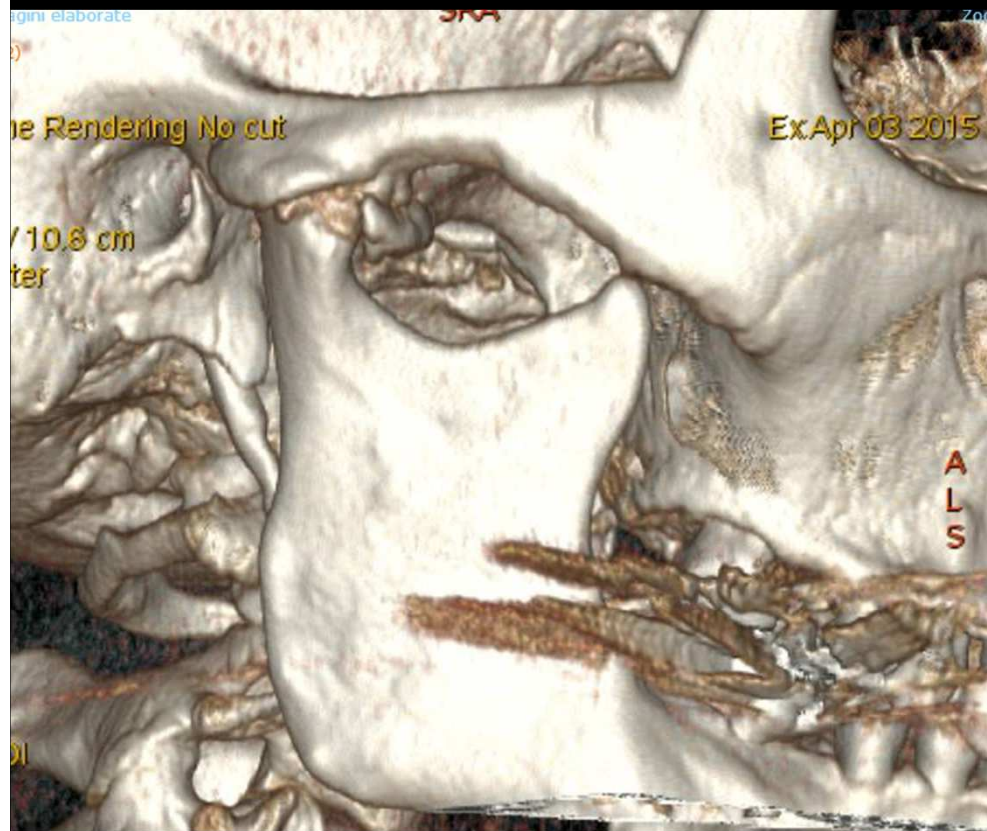
# CONDROMATOSI SINOVIALE





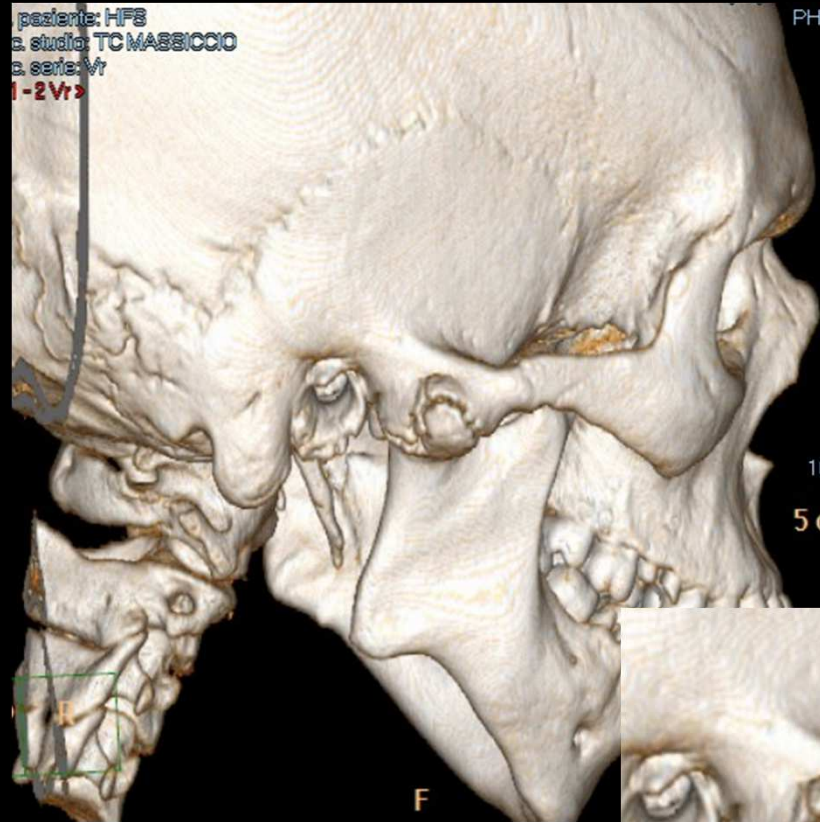
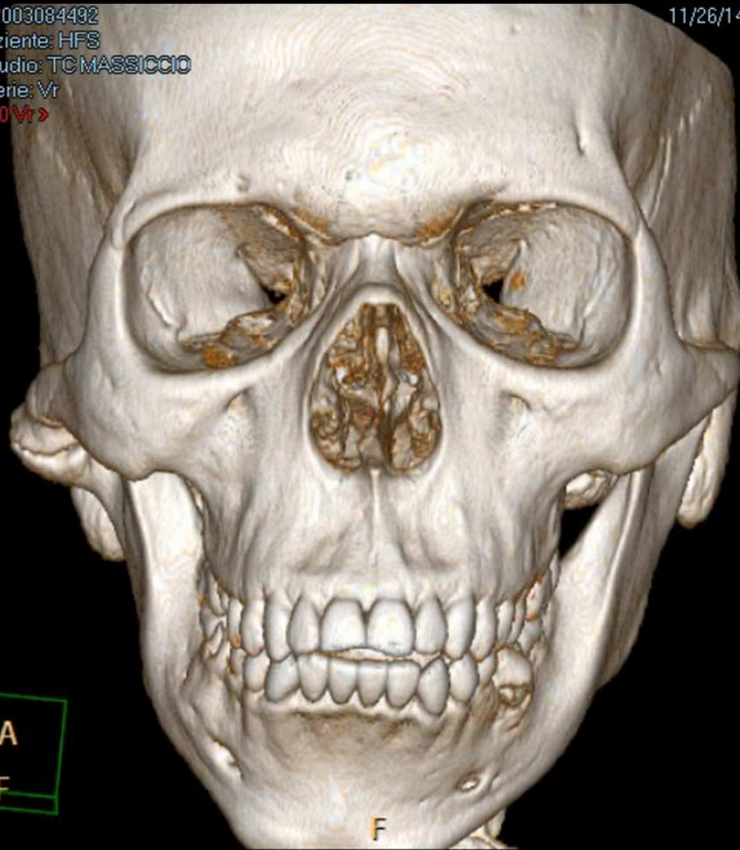
# ARTROSI



# ANCHILOSI TEMPOROMANDIBOLARE

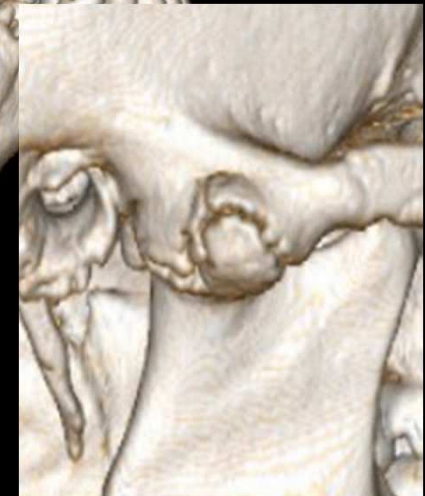F: 92003084492  
paziente: HFS  
c. studio: TCMASSICCIO  
c. serie: Vr  
1-10Vr>

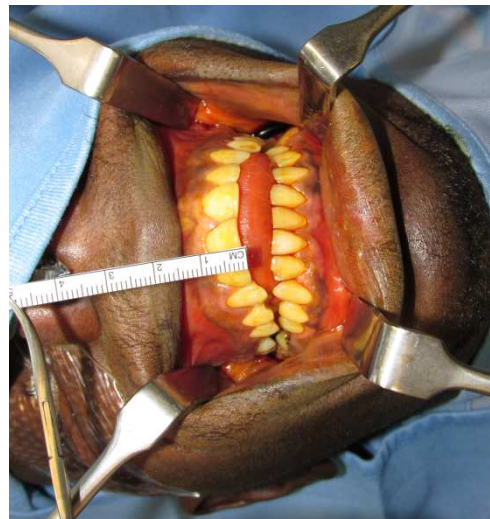
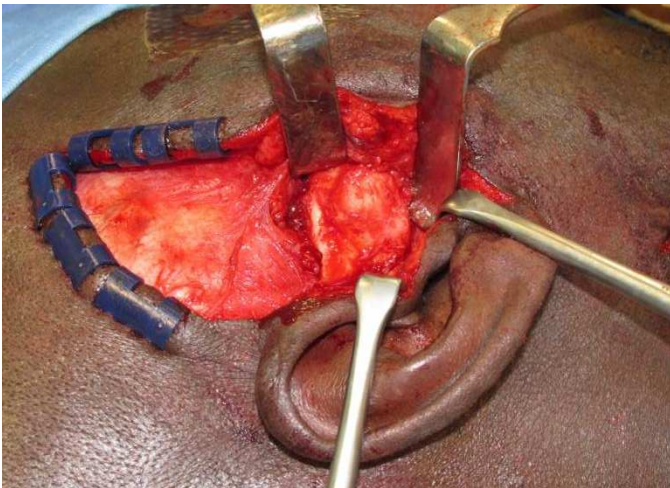
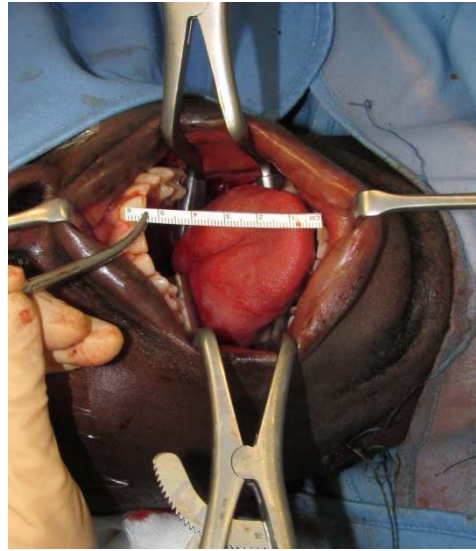
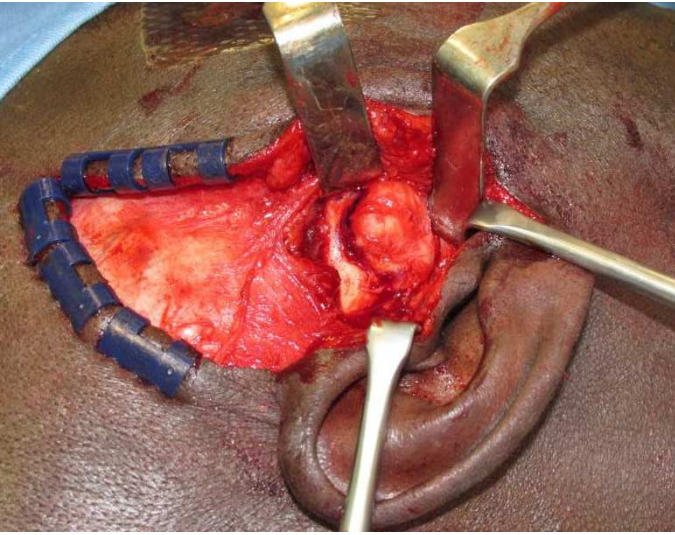
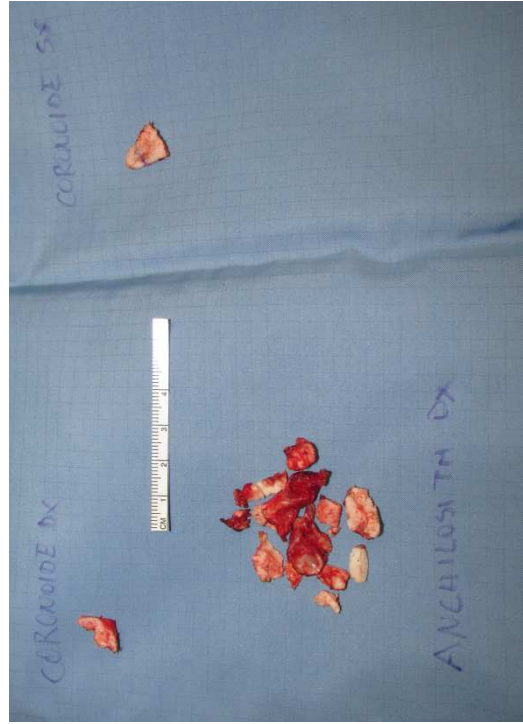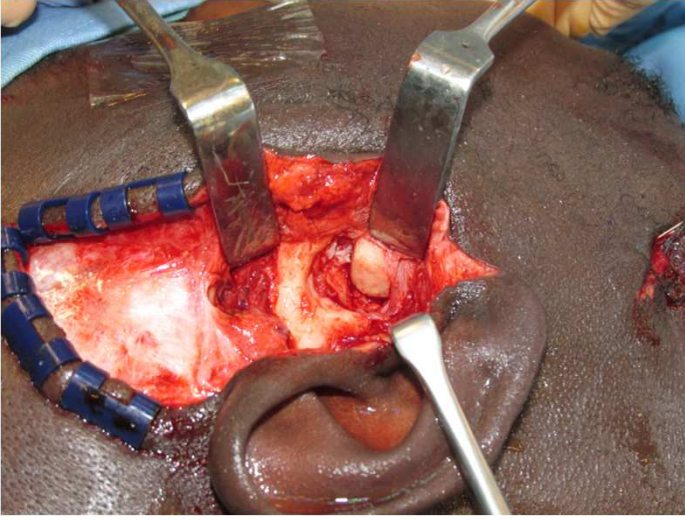
11/26/14.

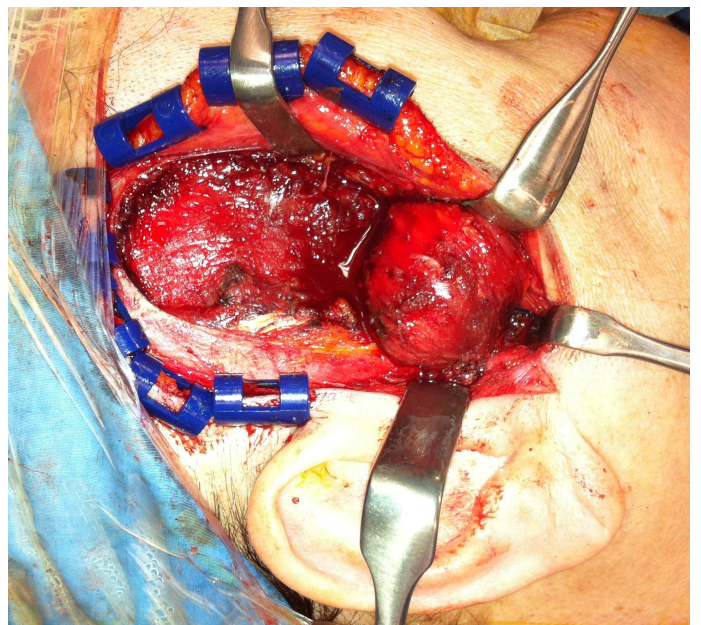
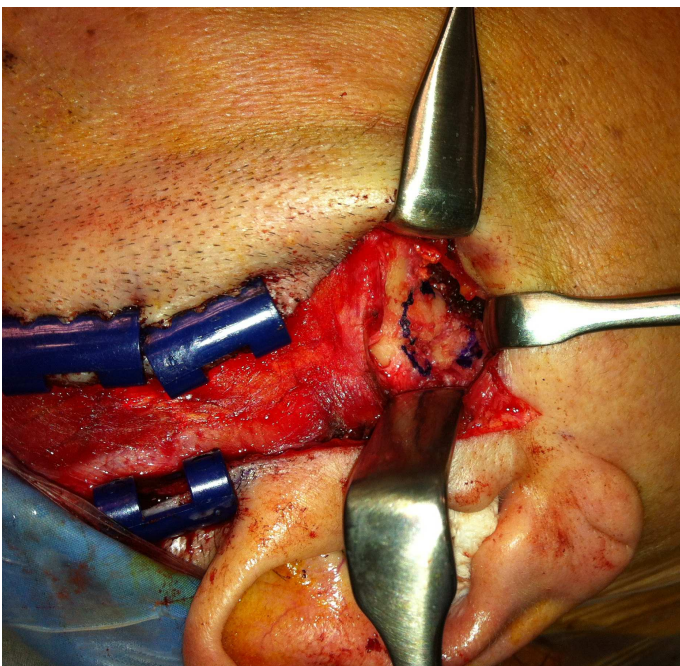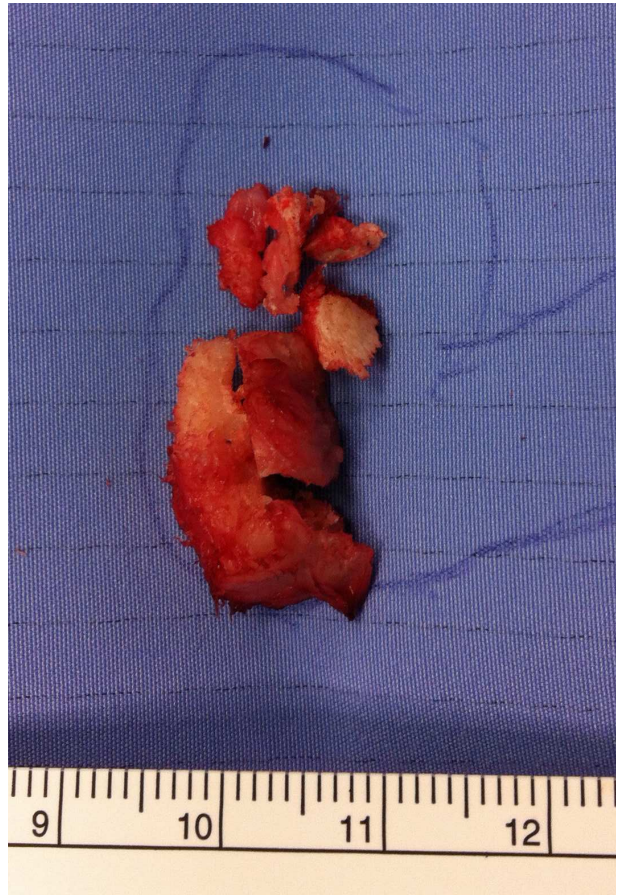



10I

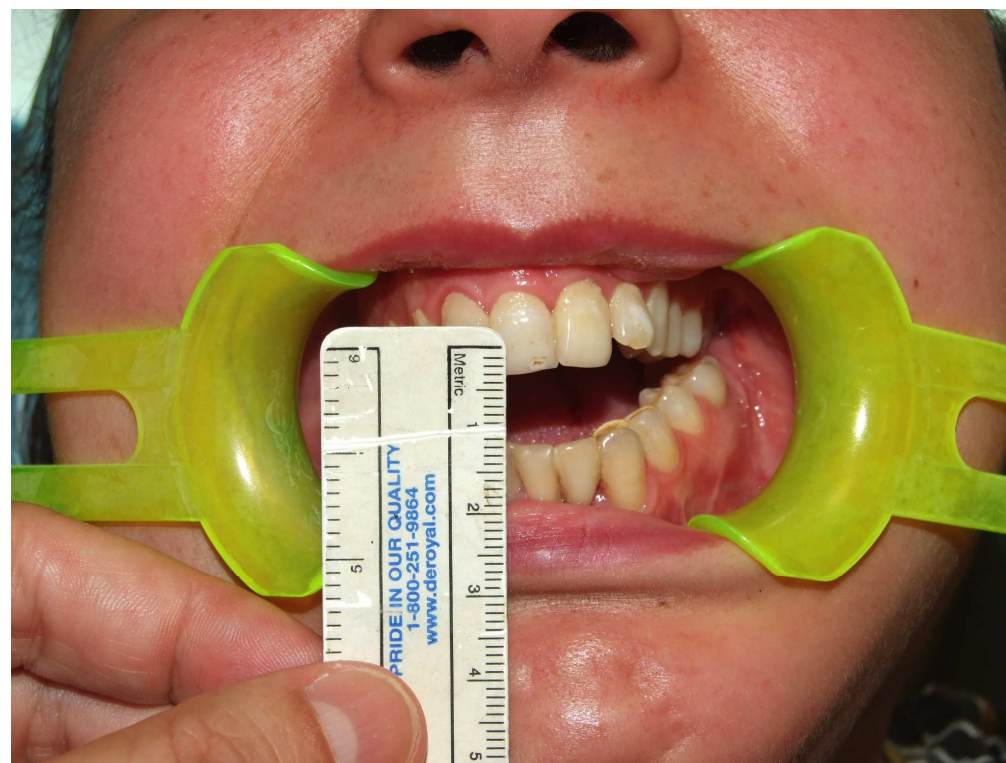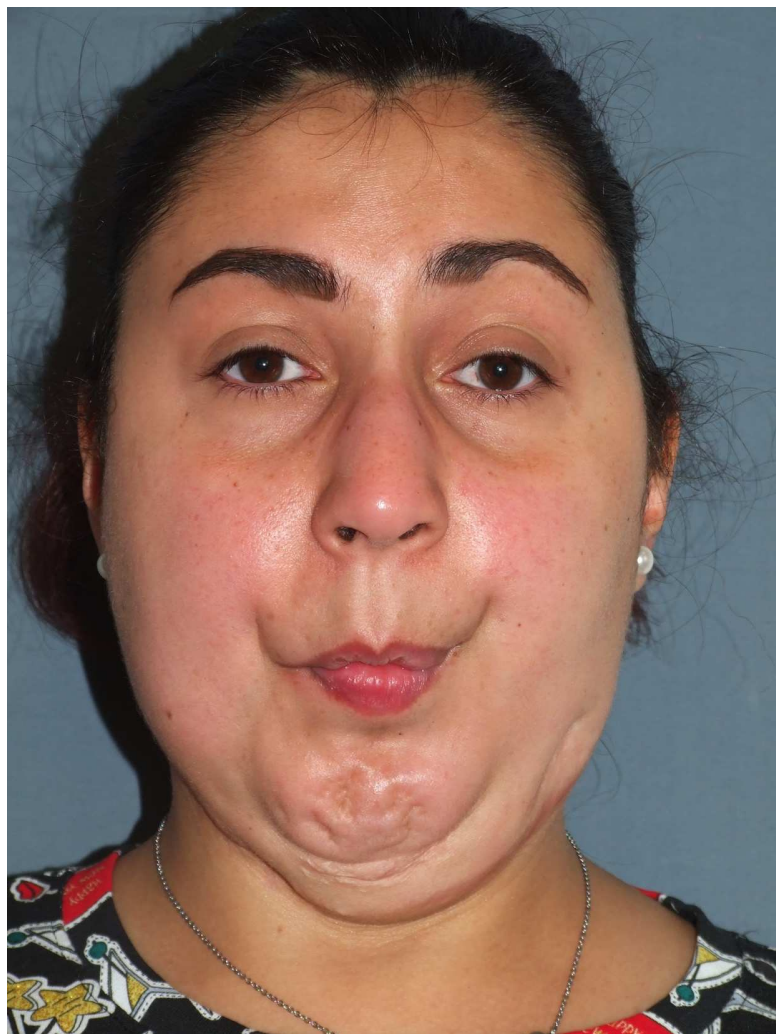
5C

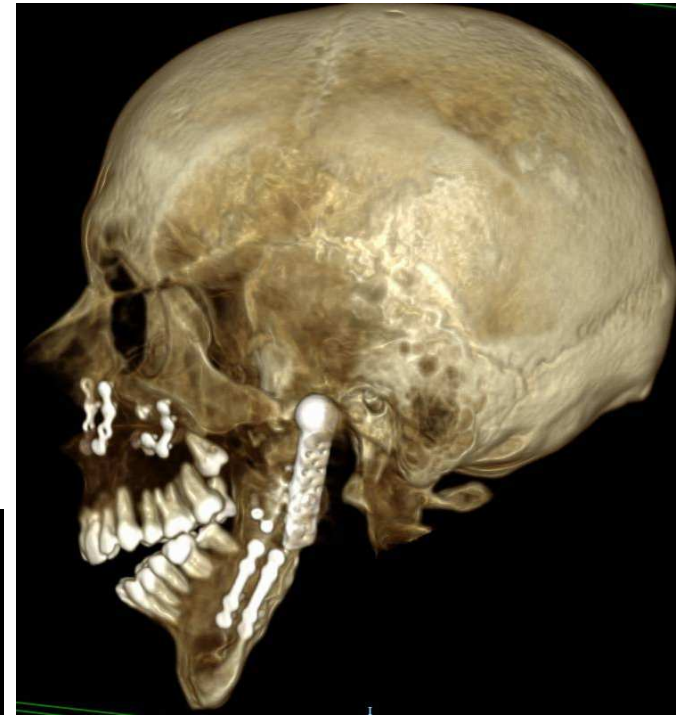
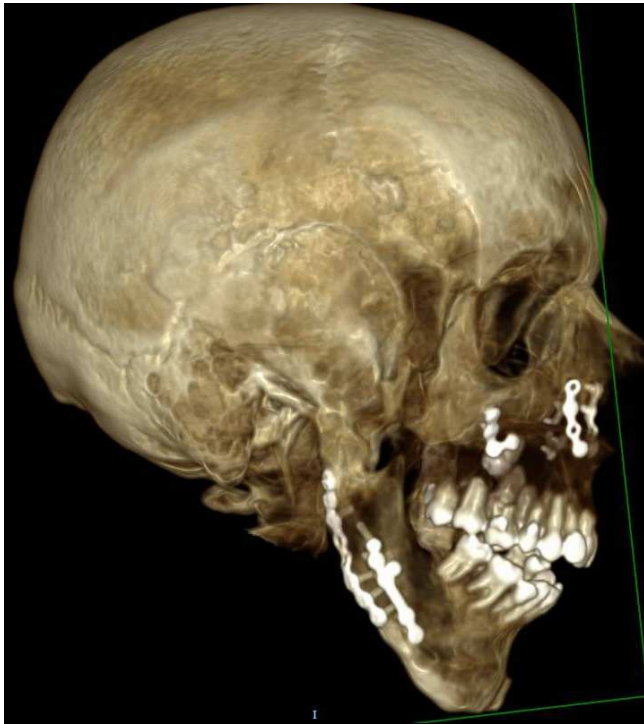




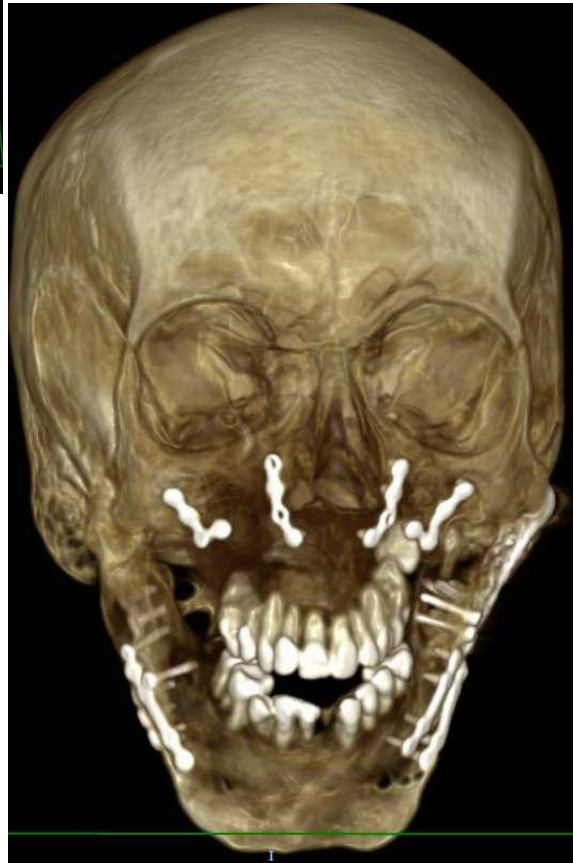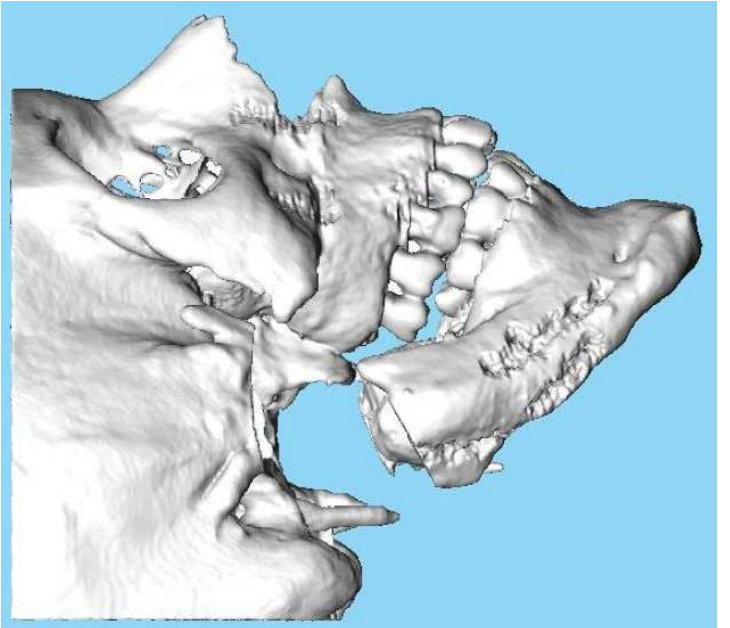
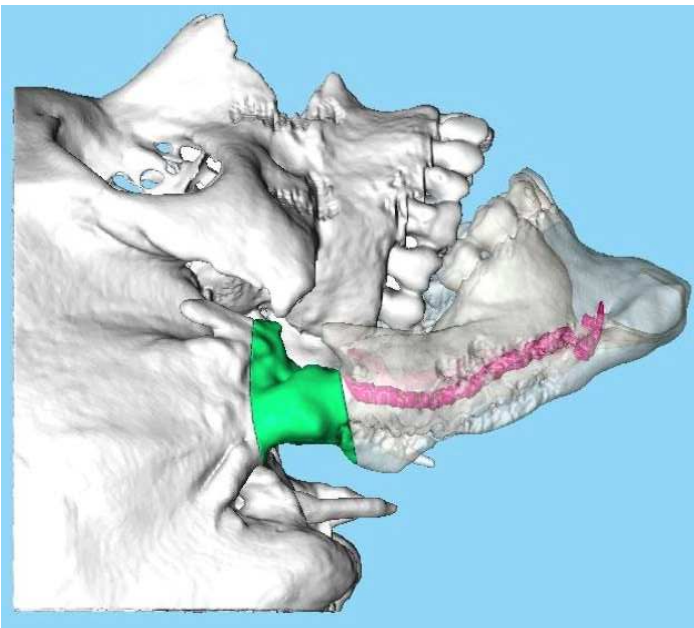
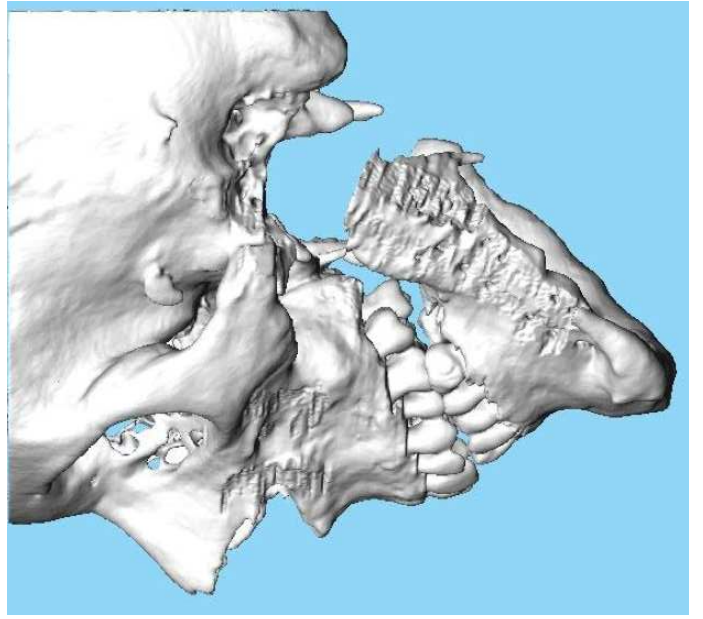
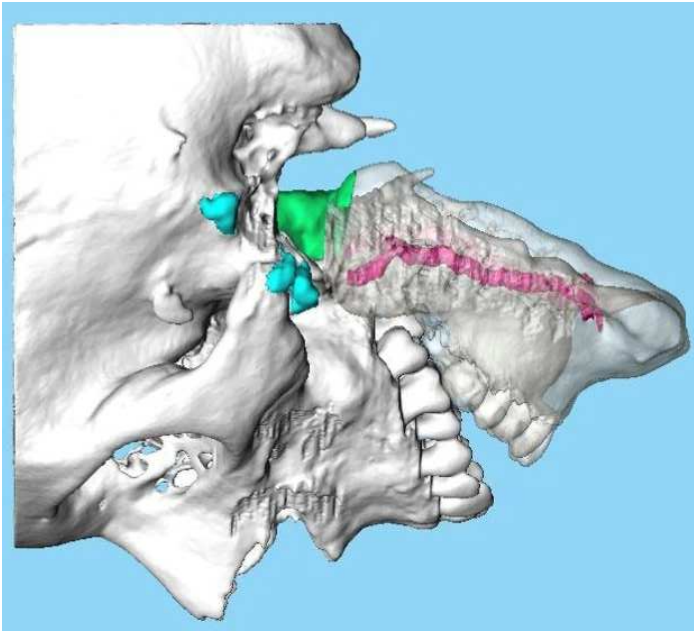
## ANCHILOSI E REANCHILOSI IN S. DI PIERRE ROBIN






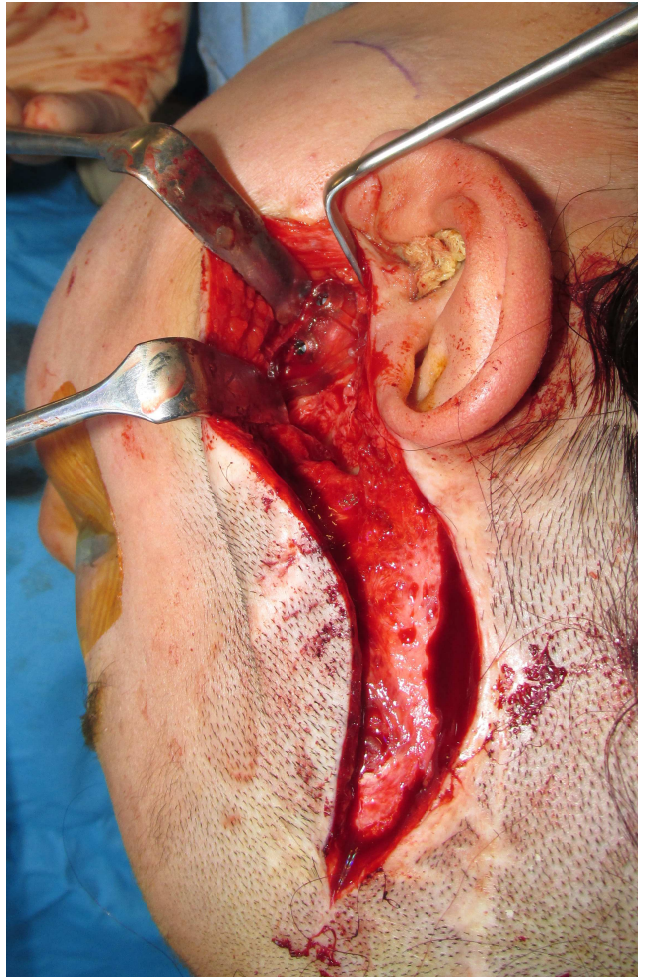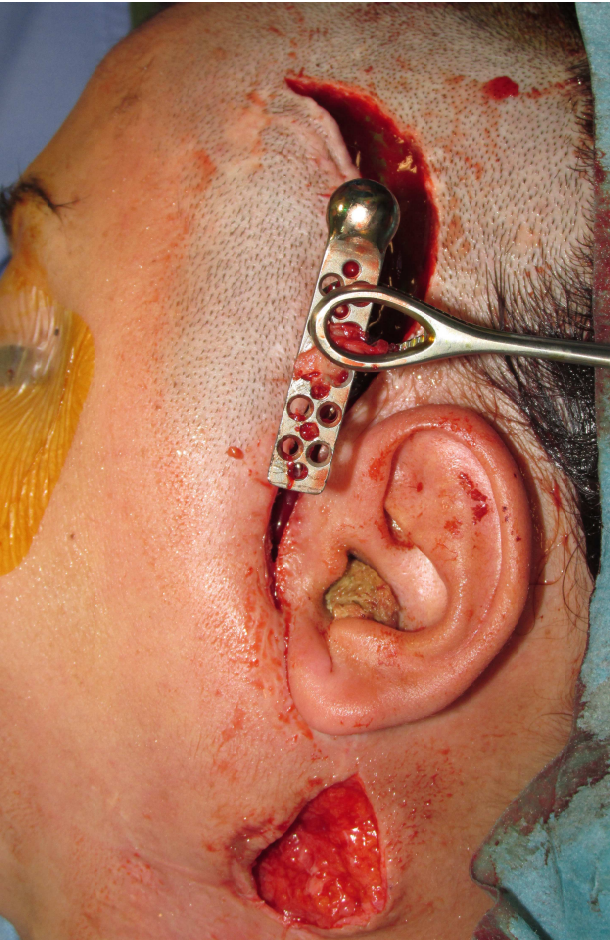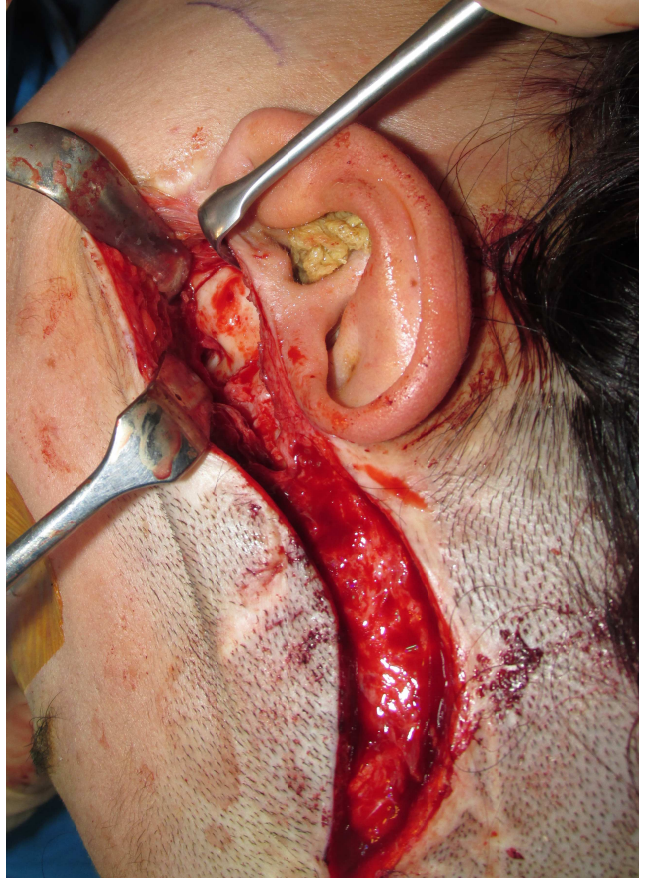
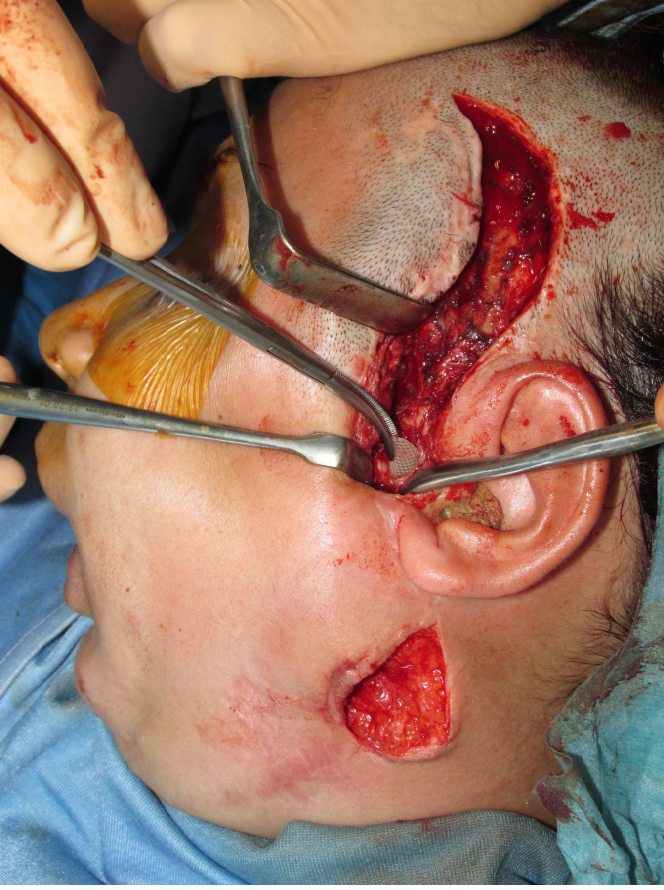


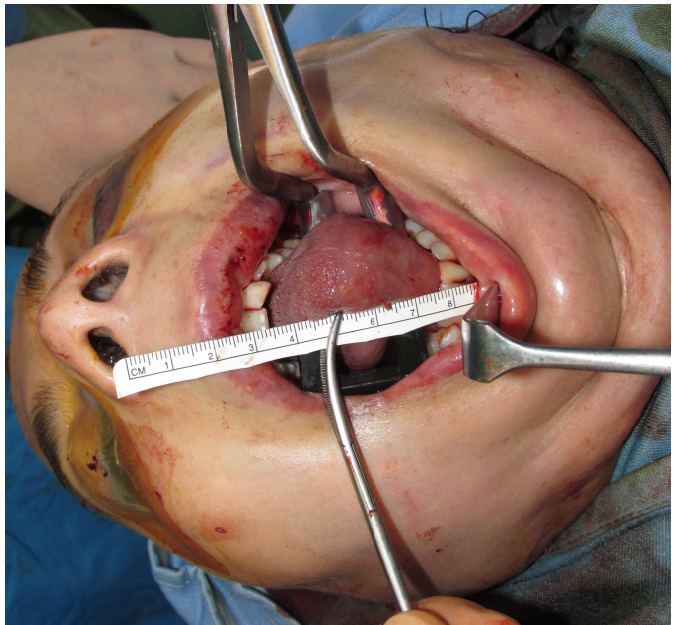
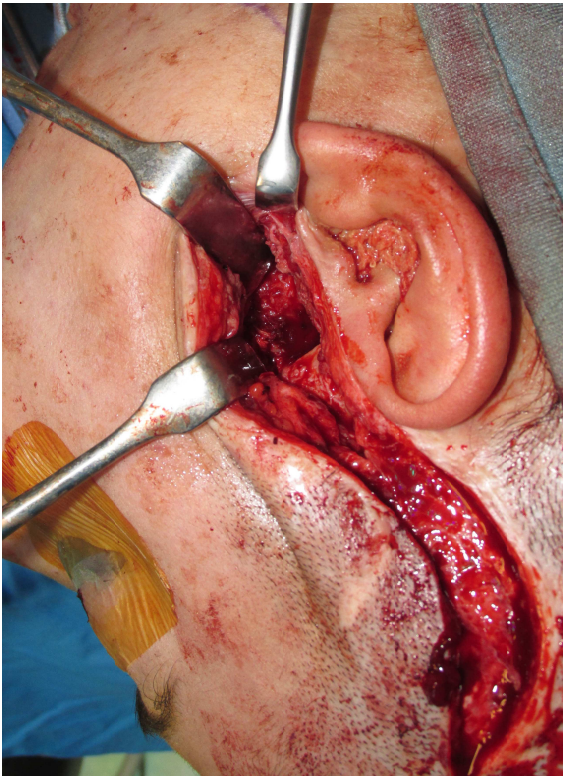


**2018**









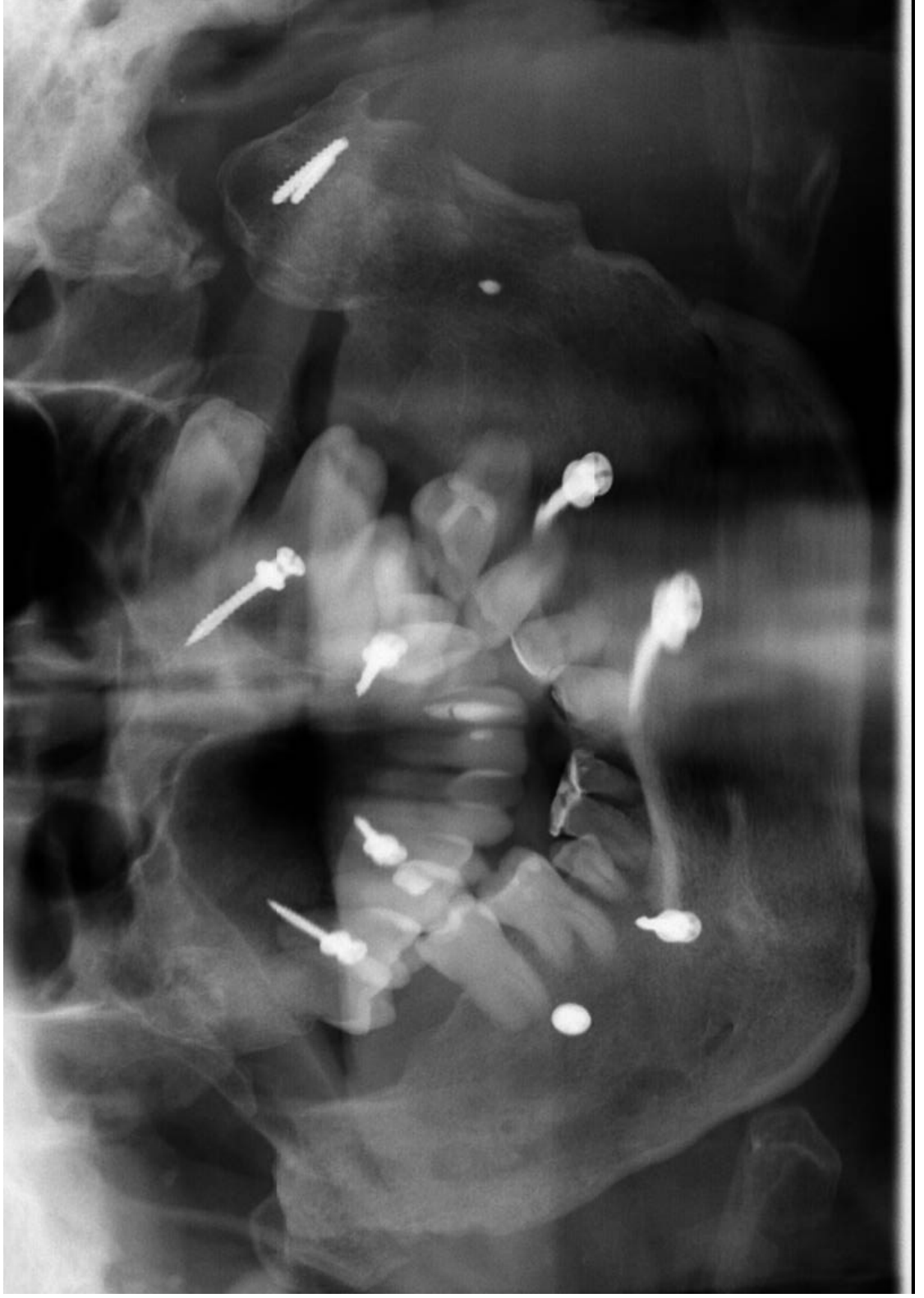

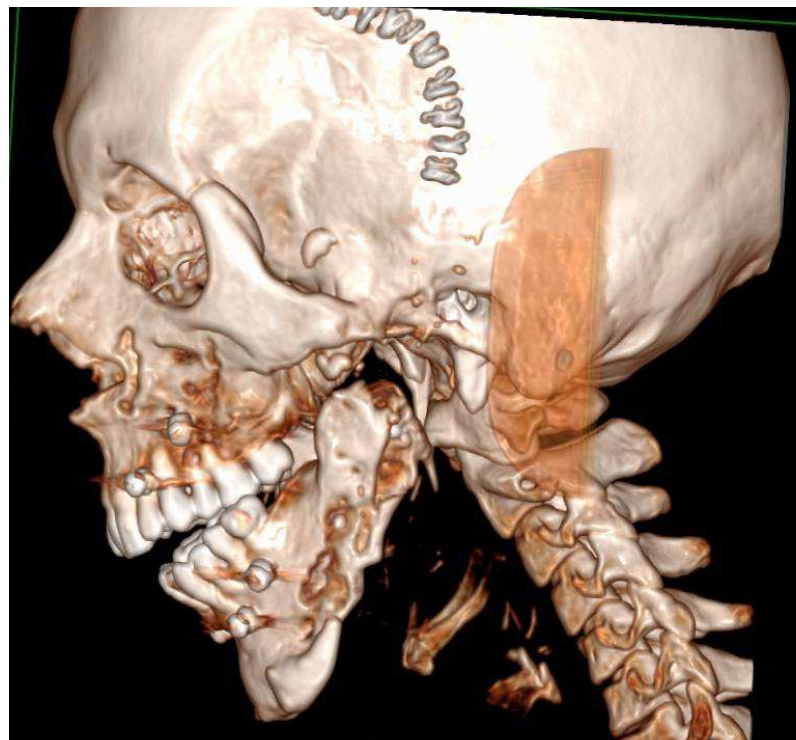
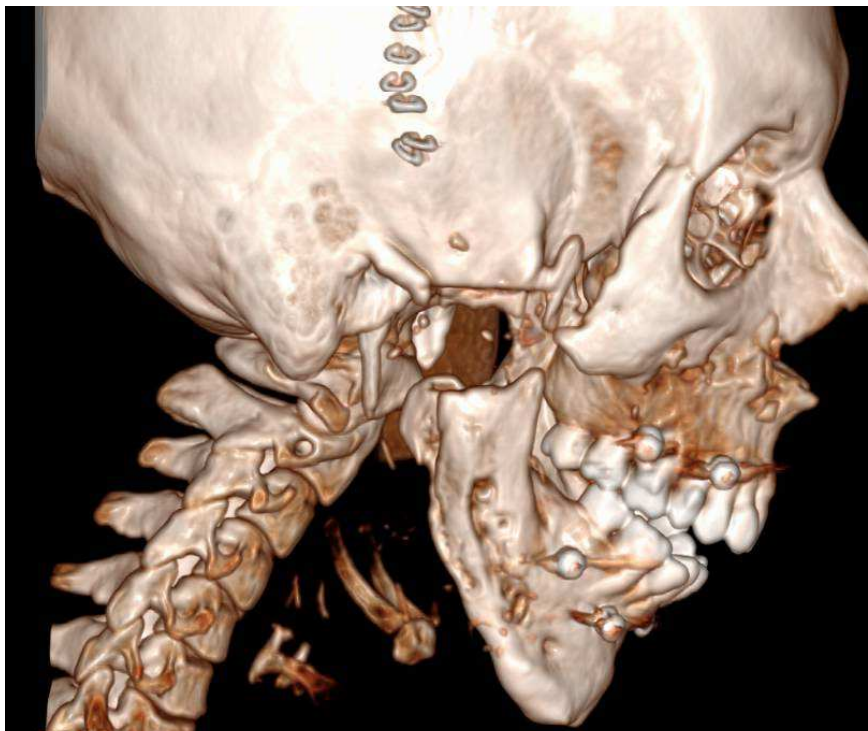


SERVIZIO SANITARIO REGIONALE  
EMILIA-ROMAGNA  
Azienda Ospedaliero - Universitaria di Ferrara

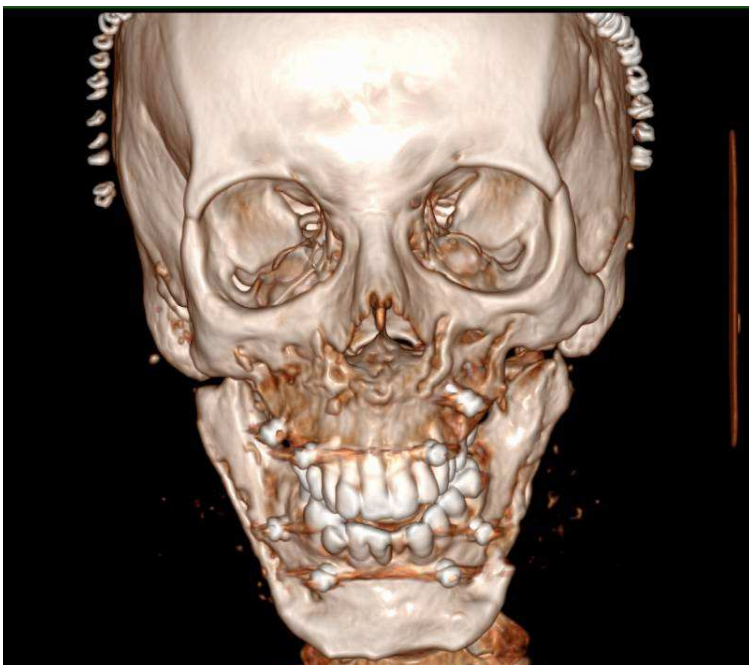

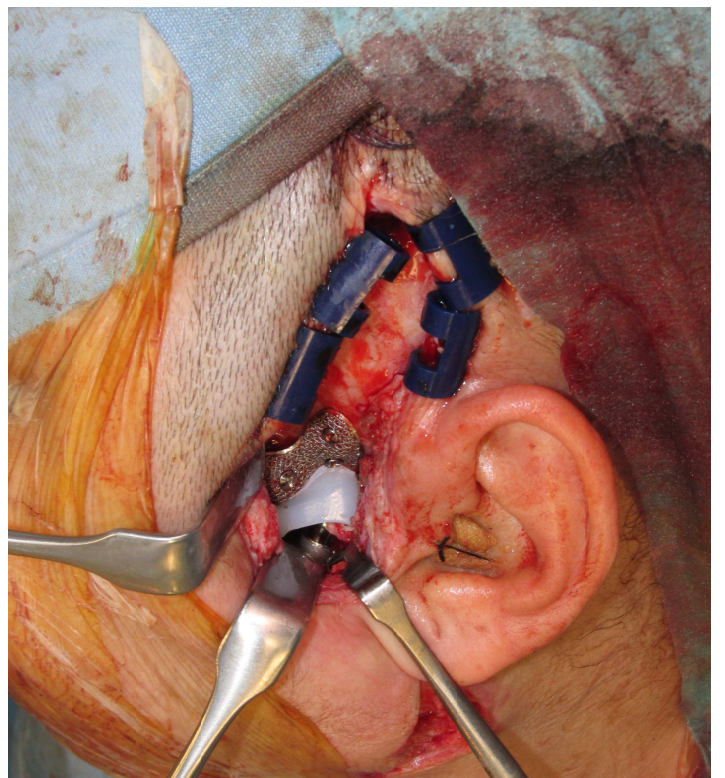
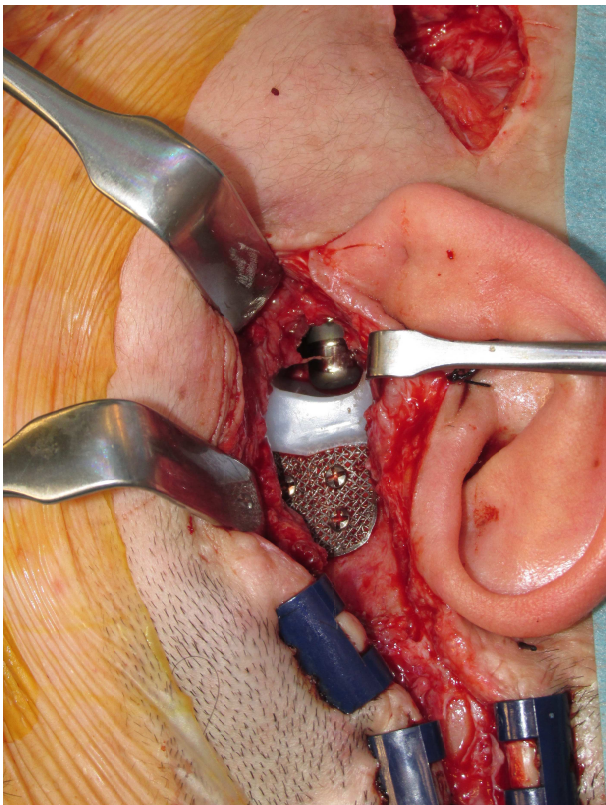
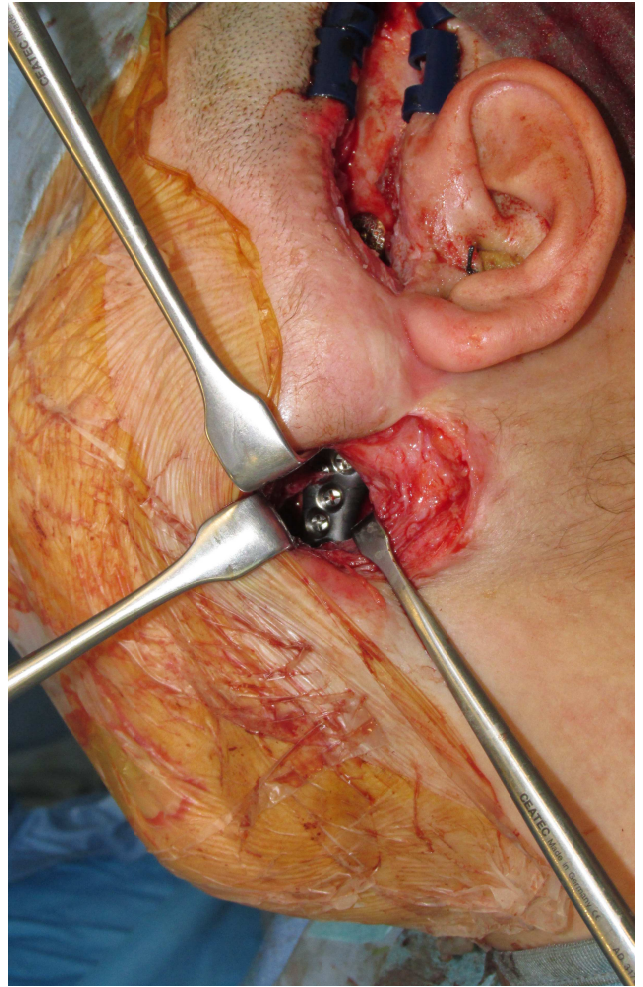
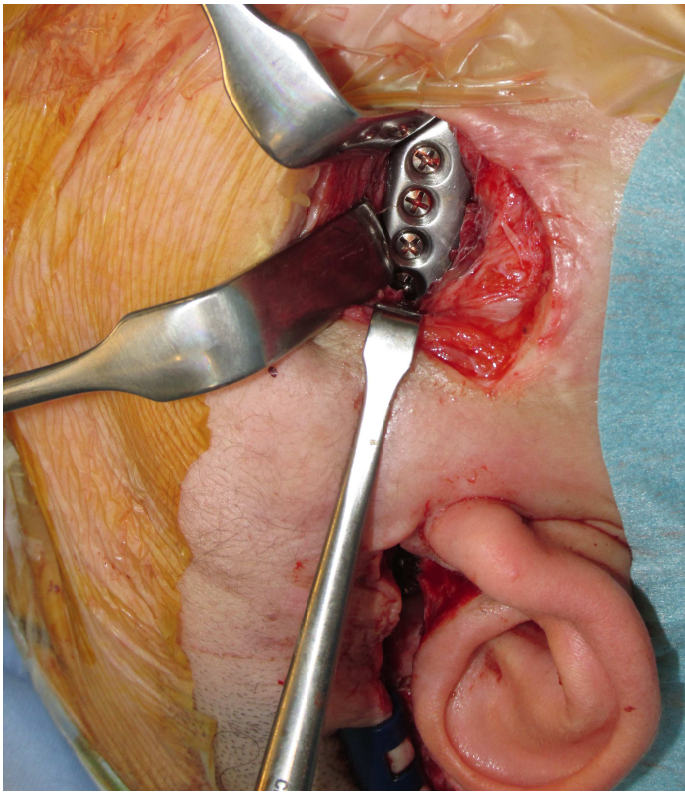
Università  
degli Studi  
di Ferrara




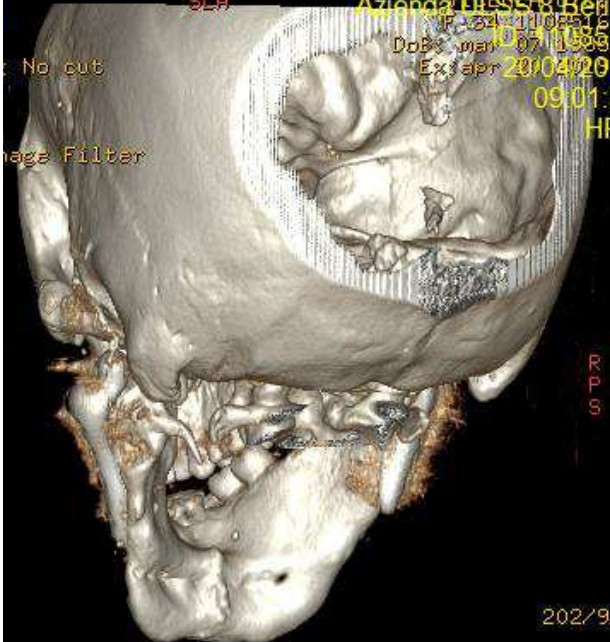
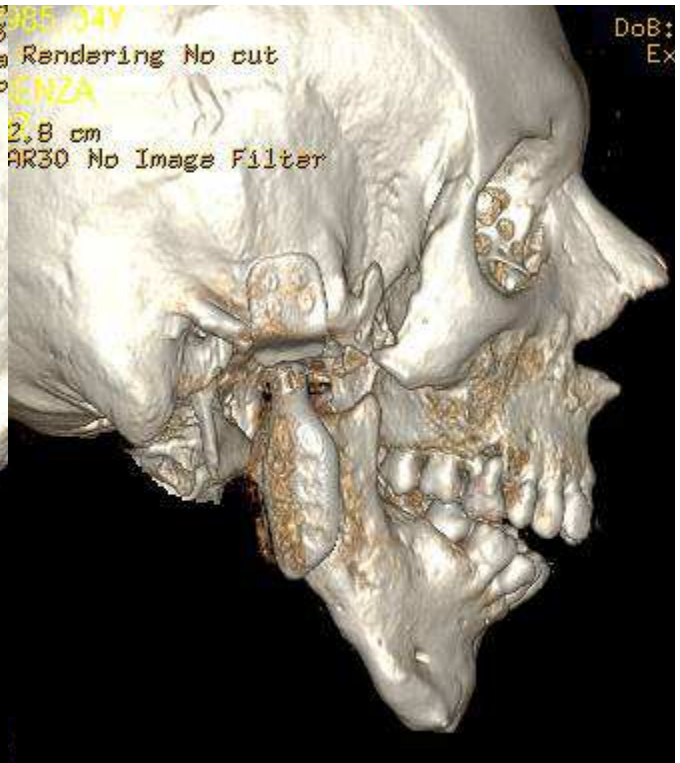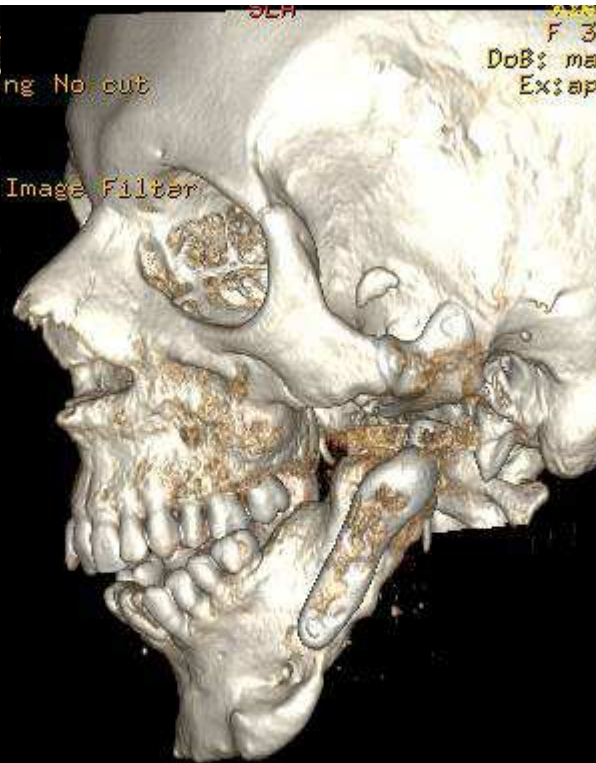
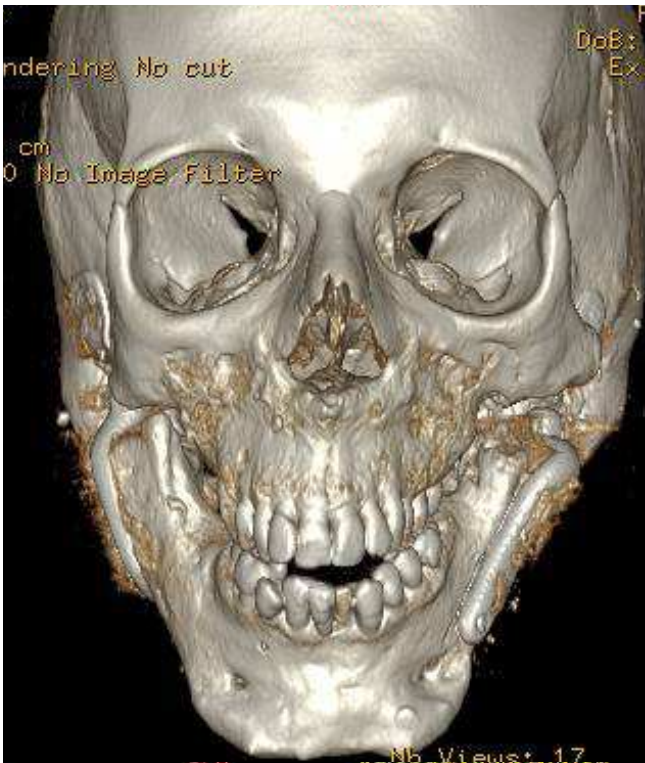

**CT after first stage**

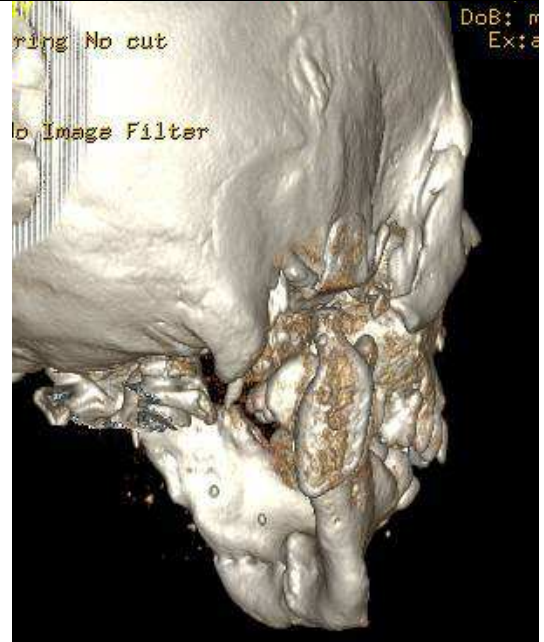








**CT scan after  
prosthesis**

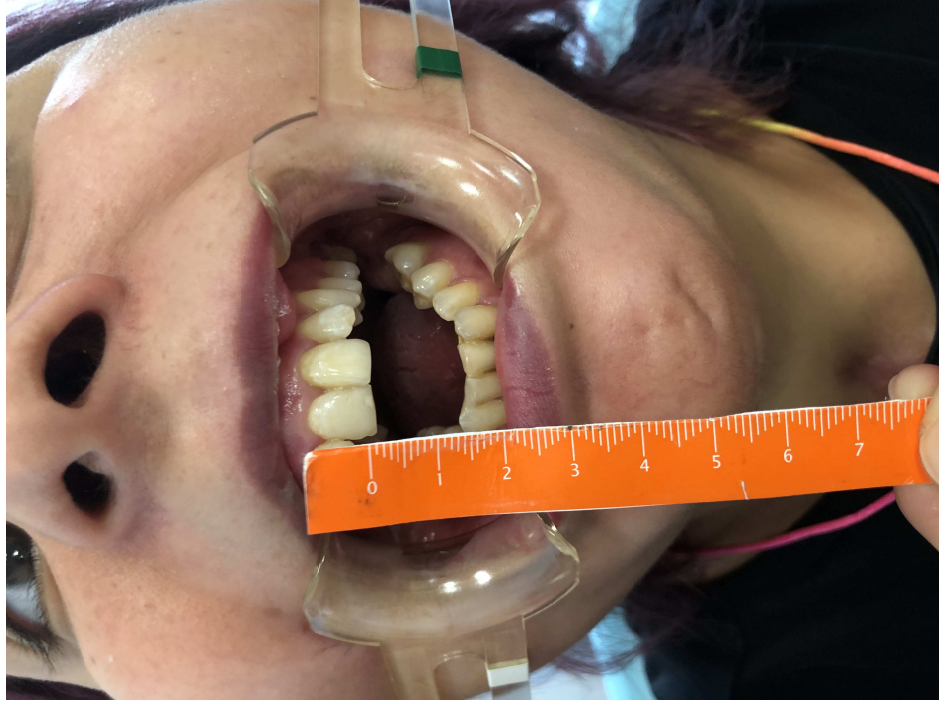
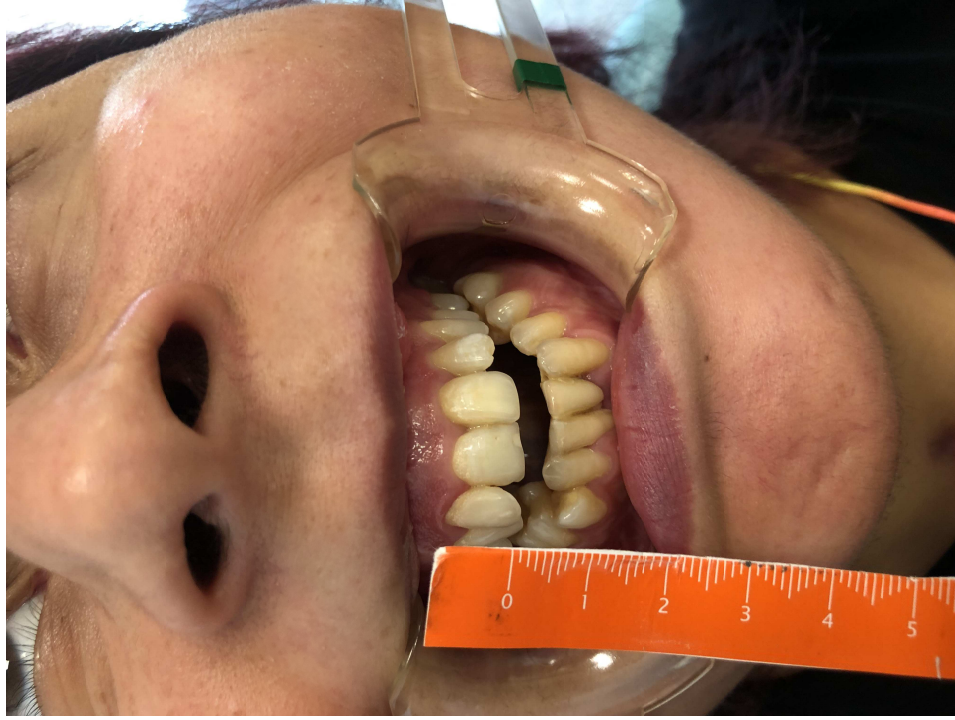


SERVIZIO SANITARIO REGIONALE  
EMILIA-ROMAGNA  
Azienda Ospedaliero - Universitaria di Ferrara



Università  
degli Studi  
di Ferrara



## CONCLUSIONI:

**- SE LA COMPONENTE MUSCOLARE E' LA CAUSA PRIMARIA E PREDOMINANTE, IL PAZIENTE DOVREBBE ESSERE APPROCCIATO CON METODICA CONSERVATIVA**

***- NON E' APPROPRIATO PREFERIRE SEMPRE UN APPROCCIO NON INVASIVO AD UNA TERAPIA CHIRURGICA SE IL PROBLEMA E' ARTICOLARE***

**- LA CHIRURGIA E' UNA SCELTA TERAPEUTICA**

**GRAZIE PER LA VOSTRA  
ATTENZIONE**